

Oral Diagnosis

50 slides- about 1.5-2 hour

Diagnosing the
Patient in Pain


Learning Objectives

1

1. Explain the steps in the pain diagnosis process
2. Identify the possible sources of orofacial pain
3. Relate the three types of nerve fibers found in pulp and how their responses are critical in diagnosing pain
4. Interpret from symptoms and radiographic appearance if pain is likely to be pulpal or periodontal in origin.
5. List which questions to ask from the mnemonic OLD CARTS, including follow-up questions.
6. Associate which symptoms relate to common pain diagnoses
7. Relate test results to common pulp, periodontal, or other diagnoses

Figuring out pain...

2



- **Your patient will almost always give you the information** you need to make a correct diagnosis ***if you ask the right questions.***
- But this process isn't always straightforward. Expect some confusing symptoms.
- You must evaluate **all symptoms** to come up with an accurate understanding of what's going on.
- In this tutorial, we're going to teach you a system for approaching a patient in pain, an **algorithm***, so you can get to a reasonable diagnosis.

Diagnosing Pain

History

- Ask “What brings you in today?” The answer is the **Chief Complaint (CC)**.
- Ask a **focused series of questions** to draw out specifics about **this** problem. In doing so, you will develop the **History of Present Illness**.

Hypothesis

- Develop a **working diagnosis**- Evaluate all of the symptoms against your knowledge of the pathophysiology of orofacial pain to identify the most likely problem in the most likely tooth/teeth. But still keep an open mind!

Test

- **Confirm or disprove your hypothesis by doing a clinical exam and tests:**
 - **“Vitality tests”** Cold and electric pulp tests
 - **Percussion and Palpation**
 - **Periodontal probing**
 - **Radiographs**

Diagnosis

- Develop a diagnosis consistent with the history, physical signs, and the results of the clinical tests.
- If these don’t add up- consider a referral to a specialist or physician

Clinical actions

Thought process

Back

Oral Pain Overview

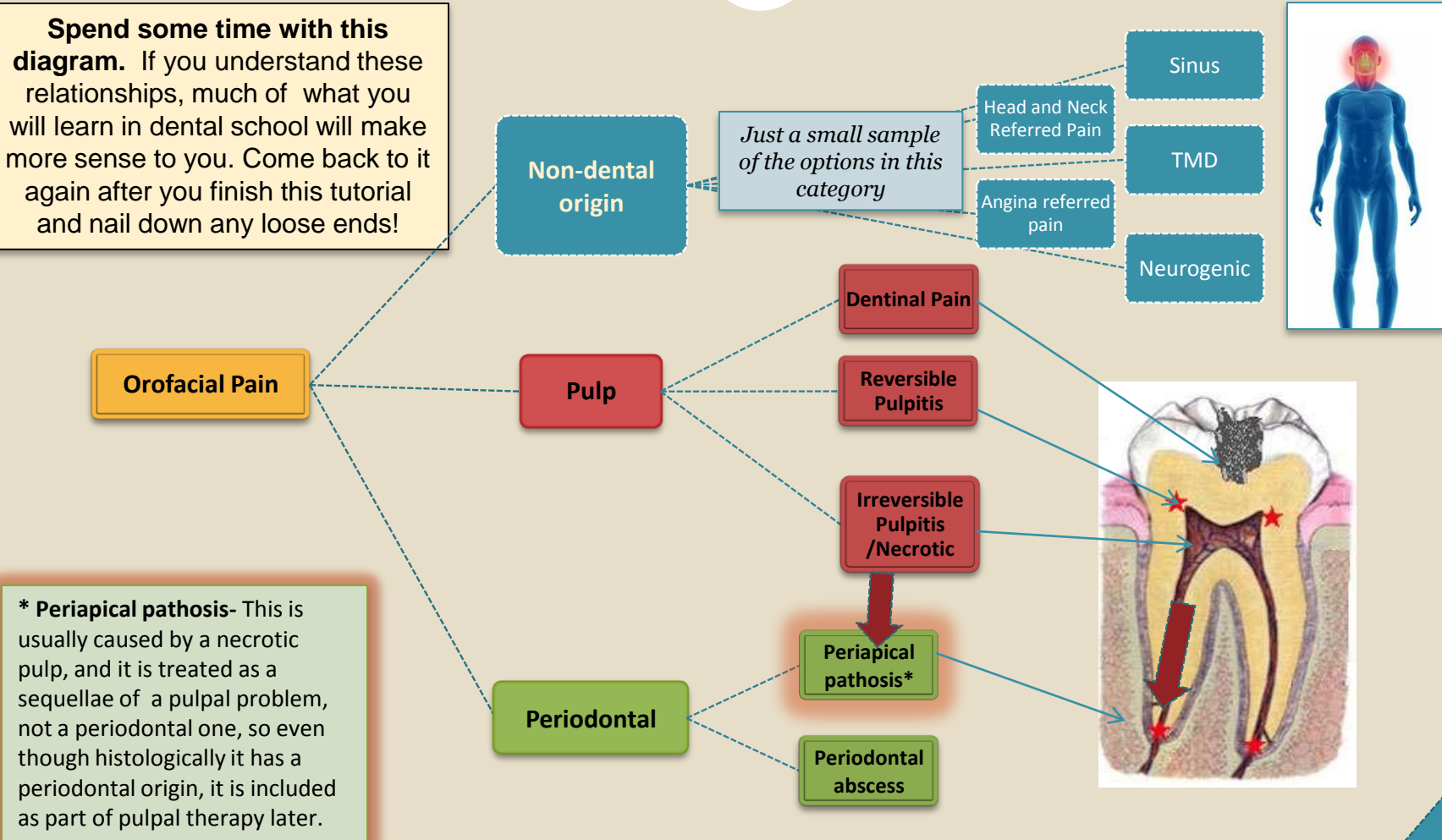


- **WHAT TYPES OF ORAL DISEASE USUALLY CAUSE PAIN?**
- **WHAT NERVE FIBERS ARE INVOLVED?**
- **WHAT DIFFERENT TYPES OF PAIN TELL US ABOUT THE SOURCE**

Diagnostic Options: Overview

4

Spend some time with this diagram. If you understand these relationships, much of what you will learn in dental school will make more sense to you. Come back to it again after you finish this tutorial and nail down any loose ends!



* **Periapical pathosis**- This is usually caused by a necrotic pulp, and it is treated as a sequellae of a pulpal problem, not a periodontal one, so even though histologically it has a periodontal origin, it is included as part of pulpal therapy later.

How do we figure out the source of pain?

5

- Let's leave **non-dental head and neck pain** out of our discussion for now....It's a big topic that will be addressed in other courses except for knowing how to categorize types of pain.
- **Periodontal pain** is fairly straightforward, since it is a result of inflammation and therefore usually easy to localize. You're going to learn more in Perio, of course, but we're going to look at the whole picture and comparisons for clarity.
- That leaves the **pulp**, which is the **wild card** in oral pain. Why?
 - You **can't see** inside a tooth...
 - ...and you can't always judge the **type or amount of pathosis** by the amount and quality of the pain...
 - ...so, it's tough to figure out! But when you understand the **innervation of a tooth**, things become much clearer. So, let's take:

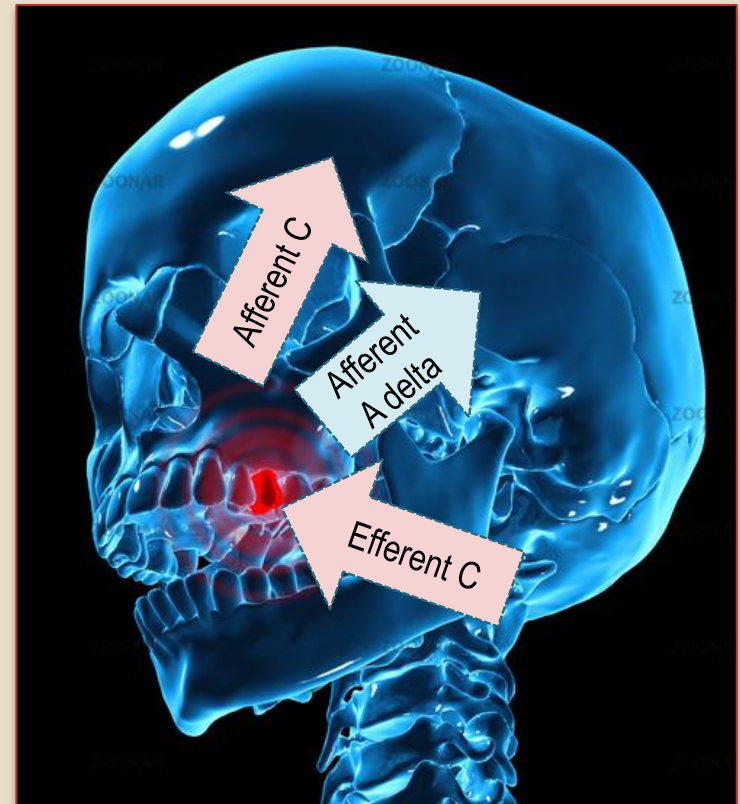


A short trip into the pulp...

Only three kinds of nerve fibers in pulp:

6

- ***The good news?*** It's not that complicated. There are only three different types of nerve fibers in pulp, and really, only two of them (the afferent, or sensory fibers) are really important.
- ***Why does it matter?*** We have very little way of knowing what's happening inside the pulp...can't see anything with an x-ray, can't touch it.
- All we have is the indirect evidence of **which nerves are active**, because this **indicates the histologic status of the pulp tissue**.



Let's look at each in detail...

Afferent A-delta Fibers

7

- Transmit **sharp, pricking pain**.
- **Low threshold** for stimulation.
- Are stimulated by **cold** and electric pulp testing.

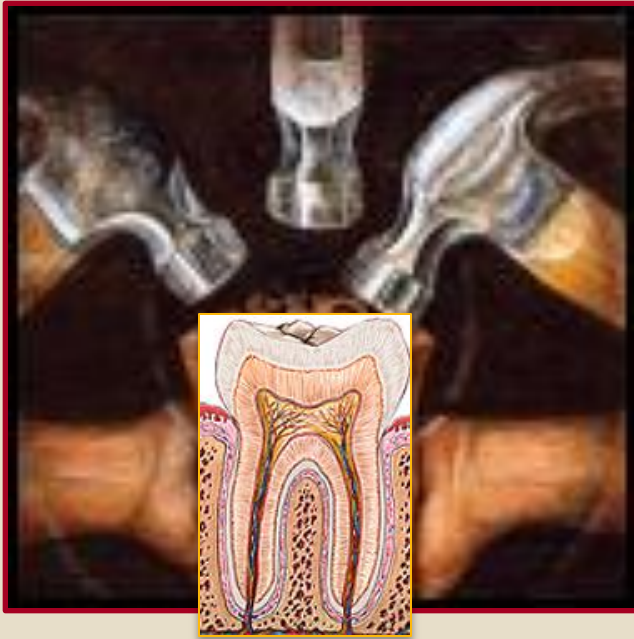
Note: These fibers are *not fully formed until 5 years after a tooth erupts*; this explains why immature vital teeth do not respond normally to electric pulp tests.



Positive, normal duration response (<30 sec) \approx
Vital pulp or diagnosis of reversible pulpitis

Afferent C fibers

8




- Transmit **burning, aching, throbbing pain**.
- Have a **high threshold** of stimulation, responding only when tissue is injured.
- Are *sometimes* stimulated by **heat**.
- Remain excitable even in necrotic tissue.

Positive response \approx
Tissue damage, irreversible pulpitis

Efferent C fibers

9

- Can **constrict blood flow.....BUT** can't *dilate* blood vessels. Dilation is caused by **inflammatory products like histamines**.
- So, if there are symptoms of inflammation (throbbing, which indicates swelling, for example) it probably indicates pulpitis.



Ponder this....

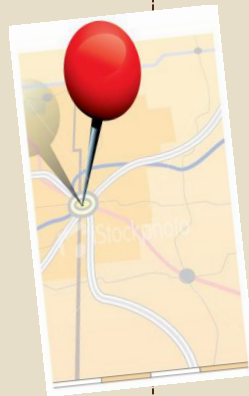
How many of these classic signs of inflammation can you detect in a pulp anyway? How?

NOTE: the pulp has no proprioceptive* fibers!

10

Pulp

- The **pulp** does **not** contain any proprioceptive* fibers.
- So, the patient has trouble reliably localizing pain if *only* the pulpal nerve fibers are involved.



Periodontal ligament

- The **periodontal ligament** **does** contain proprioceptive* fibers.
- The patient **can** localize their pain when inflammation spreads from the pulp to the periapical tissues.

Back

Diseases and Associated Pain



- **NON-DENTAL PAIN**
- **PERIODONTAL PAIN**
- **PULPAL PAIN:**
 - **DENTINAL ORIGIN**
 - **PULPITIS**
 - **PERIODONTAL INVOLVEMENT**

Who are your pain patients?

11

- Of the patients who **present with pain, 75% have pain that comes from a diseased pulp**. Of these:

- Half have vital pulps
- Half have non-vital pulps

Mitchell and Tarplee, Painful Pulpitis:

A clinical and microscopic study, Oral Surgery, 1960

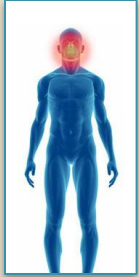
- The **other 25%** fall into:

- **Non-dental origin**
- **Periodontal origin**



Categories of Orofacial Pain: Non-Dental Pain

12



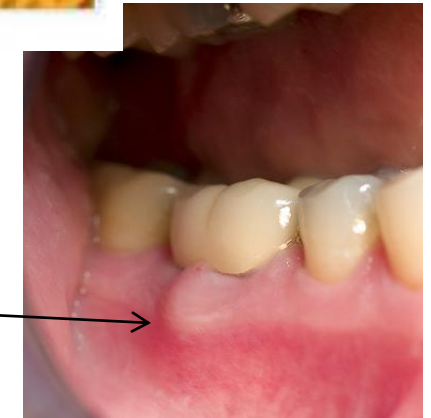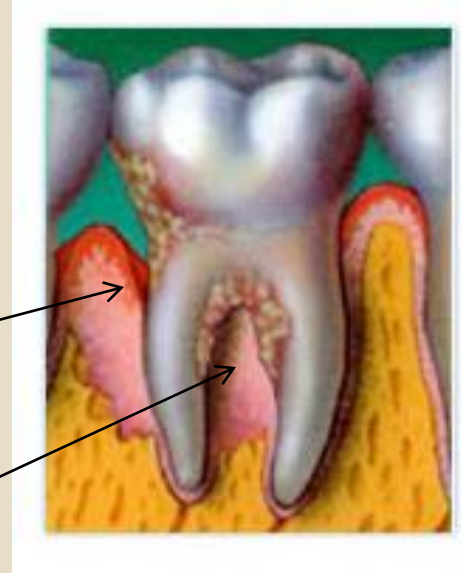- Without minimizing its importance, **non-dental pathology** is **not the most common cause** of orofacial pain. *Usually, orofacial pain has either periodontal or dental causes.*

- *But not always!!!* If your diagnosis just isn't falling into any of our usual dental bins, back up and think about the rest of the body! Don't assume it **has** to be a tooth just because it **usually** is.
- The **head and neck region is packed with complex anatomy**, its innervation is famous for **referred pain**, and the study of this type of pain is a dental specialty in and of itself (Oral Medicine, primarily). If it's not adding up to anything you can be sure of, get a referral!

Categories of Orofacial Pain: Periodontal Pain

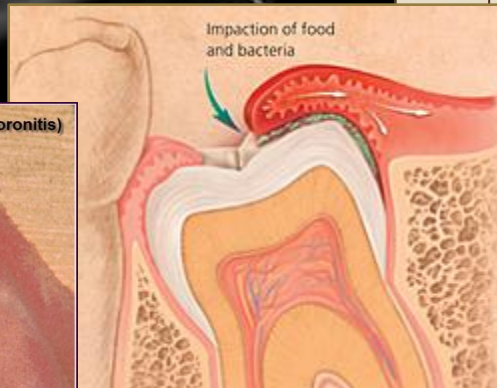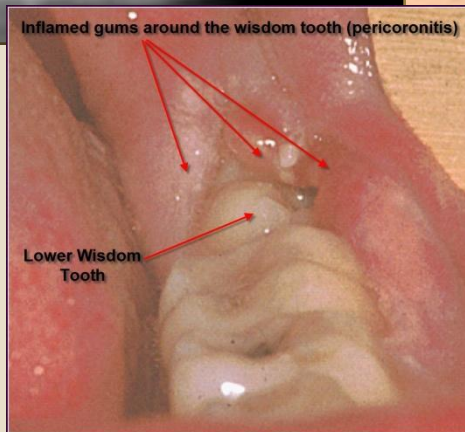
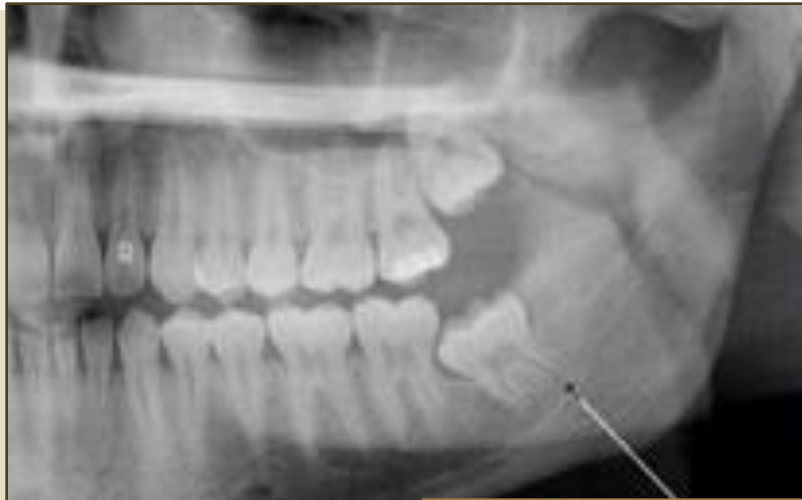13

- **Usually, periodontal disease doesn't hurt.** There can actually be a rather large amount of bone loss without any pain.
- **Why?** It's a **chronic, not acute disease**; and pus can usually drain out of a periodontal pocket, so pressure, the usual source of pain, doesn't build up.
- But as periodontal inflammation progresses **deeper** down into the bone, **pus may not be able to drain**, so it can start to hurt.
- **"Pus will out,"** and it seeks the path of least resistance; it may drain through the gingiva (gum), so look for swellings and drainage.



Periodontal Pain: Pericoronitis

14



- A special subset of periodontal disease involves **third molars** (“wisdom teeth”). Frequently these don’t have enough room to erupt into the bone in a chewing position.
- If the tooth erupts far enough into the mouth for **bacteria to get into the sac that surrounds the crown**, **pericoronitis** (*peri* = around, *coronal* = crown, *itis* = inflammation) may result. The tooth now acts sort of like a big splinter in the bone- the patient can’t clean it, and the bacteria just have a field day partying under that flap of gingiva.
- Pericoronitis almost always involves **lower, not upper, third molars**, mostly in young adults. Remember the usual eruption date for 3rd molars from your Occlusion course?

How do you tell if it's **perio** or **pulp** pain?

15

Periodontal Origin

- Usually there is periodontal disease (pockets) **in several areas of the mouth.**
- **Pus often drains** out when a perio probe is pushed into the area.
- The **pulp is vital.**
- Radiograph shows **perio-pattern bone loss.**

Pulpal Origin

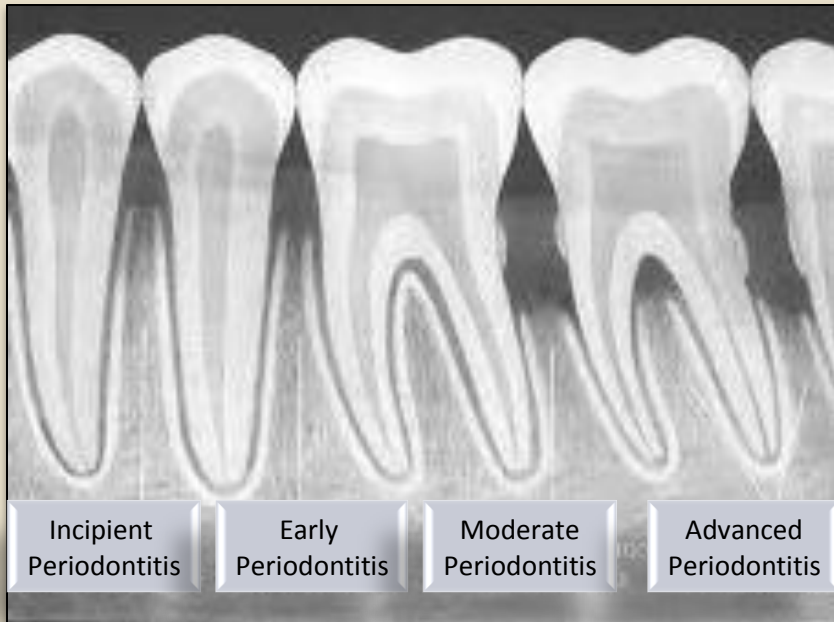
- **Sensitivity to cold**, sometimes hot.
- Usually **sharp or severe pain.**
- Usually a **history of pain** from the tooth.
- Radiograph may show **endo-pattern bone loss.**

See next slide for perio vs endo pattern of bone loss

Perio vs. Pulp Pain: Radiographic Evidence

16

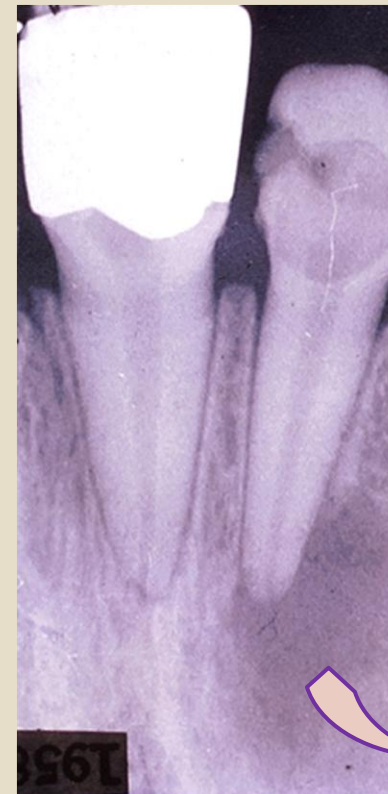
Periodontal Origin



Periodontitis (*peri*=around, *dent*=tooth, *itis*=inflammation)

is a slow, usually painless loss of bone that starts at the gum line and works down the root.

Pulpal Origin



If the **pulp is necrotic** (dead), the tissue breakdown or infection can set up an infection in the bone at the root of the tooth (periapical location) .

Note the very large composite restoration in this tooth (#7, mounted upside down for comparison with perio diagram slide)

Periapical abscess

Categories of Orofacial Pain: **Pulpal Pain**

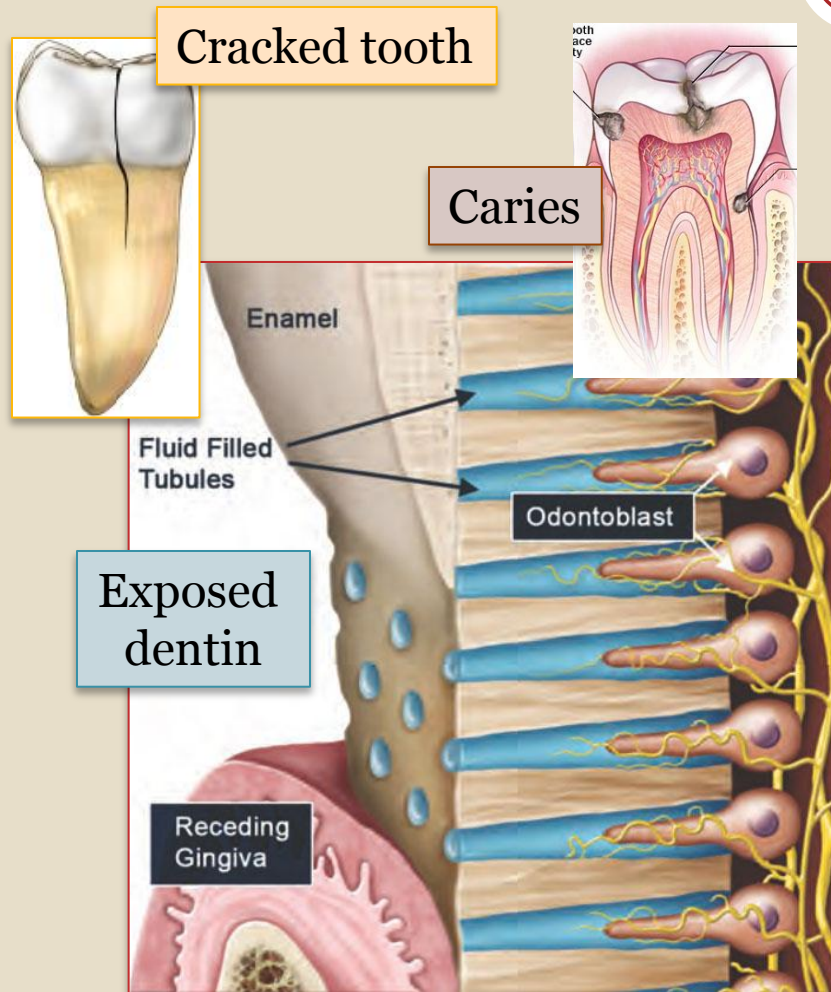
17

- Now let's start on the **remaining 75%** of your pain patients - those with pain of **pulpal origin**.
- There are three basic categories of pulp-origin pain:
 - **Dentinal pain** - Pulp is healthy, but dentinal **tubules are exposed** to the environment, which can cause pain.
 - **Pulpal pain** - The status of the pulp can range from normal to necrotic (dead), and deciding where your patient is on the scale determines what treatment you select.
 - **Periapical pain** - As mentioned earlier, as the necrotic products work out from the apex, there is inflammation and pain in the periapical area. This is theoretically another kind of periodontal pain, but since it starts from a diseased pulp, and that's how dentists treat it, we'll put it here.

Let's look at each one of these in more detail...

Pulpal Pain: Dentinal Origin

18



- Dentinal tubules are filled with fluid. If they are disturbed by air or abrasion, odontoblast nerves may fire off with sharp, electric, short duration pain. *Remember Brannström's Hydrodynamic Theory?*

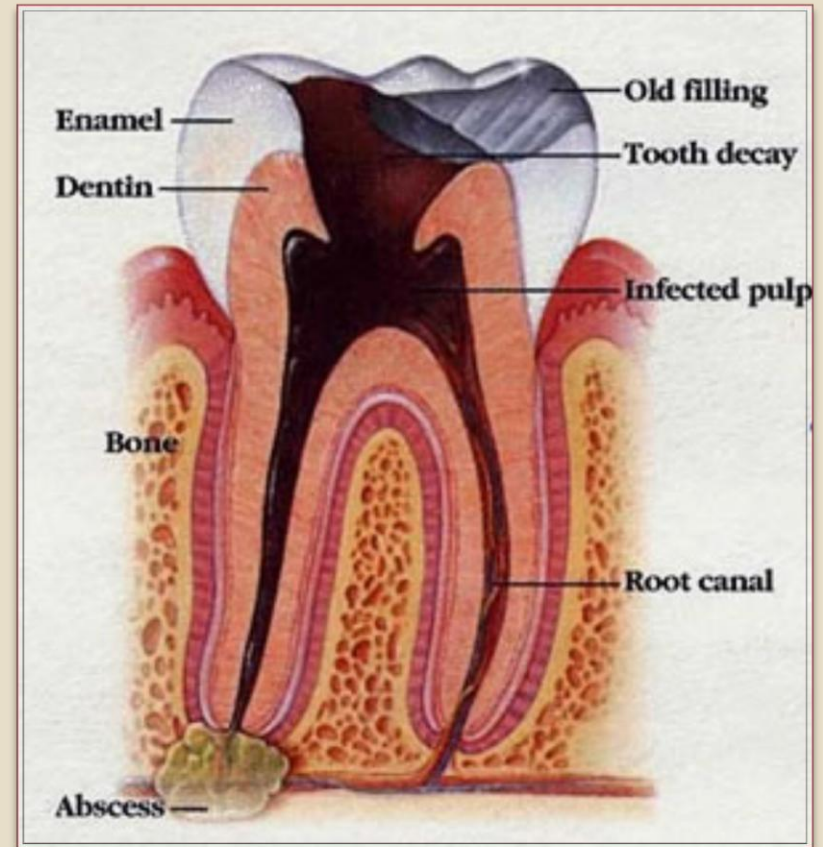
When does this happen?

- A crack in the tooth exposes tubules.
- Caries exposes tubules, which can be sensitive to air or sweets.
- Receding gums expose root surface.

Pulpal Pain: Pulpitis

19

- Decay creates an opening into the pulp for bacteria to enter.
- The pulp has defenses, but if they are overcome, inflamed tissue is trapped inside a tooth. *This hurts!*
- It's a process:
Normal → Pulpitis → Necrosis*
- There are two stages of **pulpitis**:
 - Reversible.
 - Irreversible.
 - Pulpitis can progress to necrosis.



Pulpal Pain: Pulpitis

20

Reversible



Irreversible

- Sensitive to cold, duration <30 seconds.
- History of pain days, weeks or months, but generally not getting worse.

- Sensitive to cold, duration >30 seconds.
- History of short pain duration (weeks), usually getting worse.
- Rarely, sensitive to heat.

This is the part where the symptoms don't always follow the rules.

You must ask questions, develop a working diagnosis, then do tests to confirm.

Why? Deciding between these stages of disease is crucial for treatment:

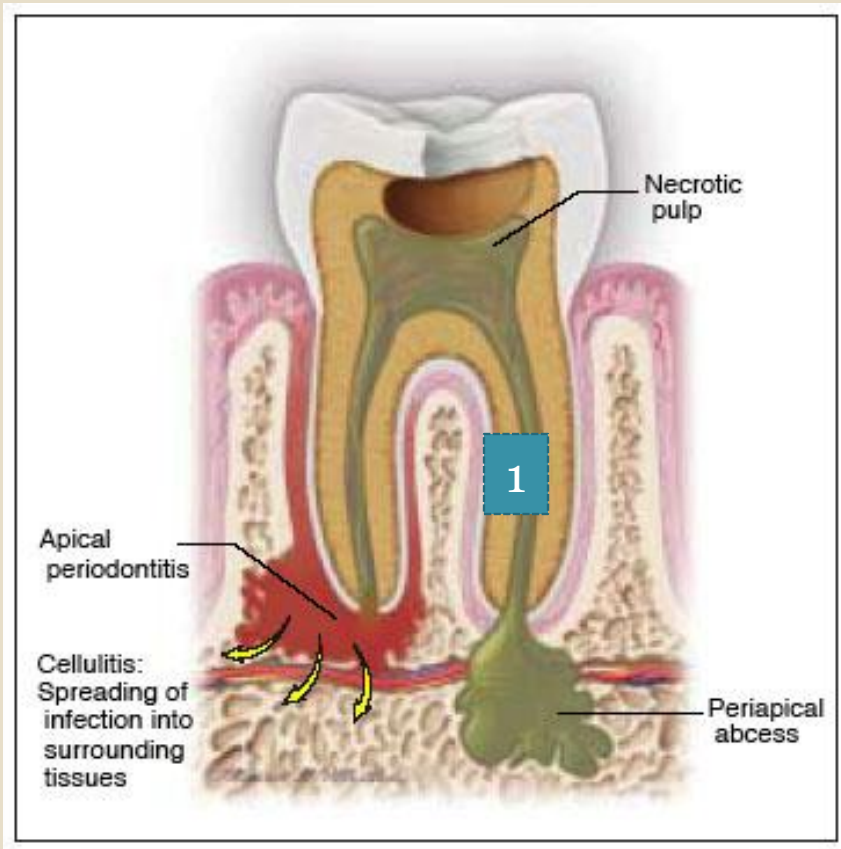
Irreversible pulpitis is treated with endodontic therapy.

Reversible pulpitis is NOT.

Pulpal Origin: Periapical Involvement

21

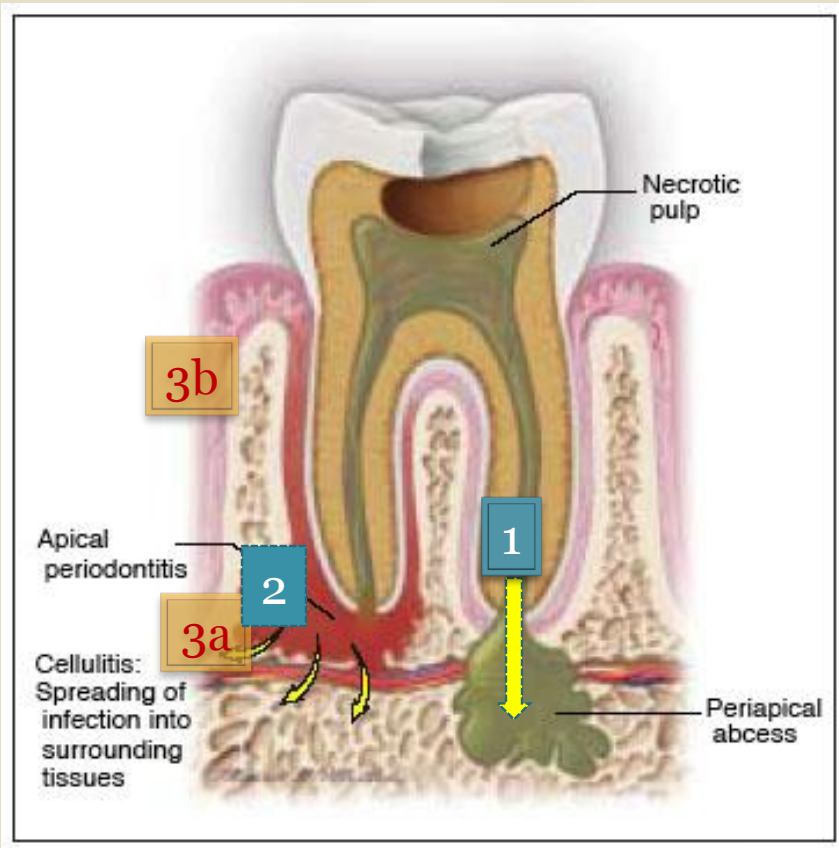
1. As the by-products of pulp breakdown **exit the end of the root** (the apex) into the bone, the tooth becomes very sore to touch, and it aches.



[Click here to see drainage path](#)

Pulpal Origin: Periapical Involvement

21



[Click here to see drainage paths](#)

1. As the by-products of pulp breakdown **exit the end of the root** (the apex) into the bone, the tooth becomes very sore to touch, and it aches.
2. At that point, the **periodontal tissue can become infected** because of the necrotic pulp.
3. The pressure of this infected pocket seeks a **weak spot** to break through:
 - a. Through the bone into **soft tissue**, like the cheek, or through to the **gum** next to the end of the root (most common).
 - b. Through the **periodontal ligament**.

Back

Case 1: Michael

22



Michael is a 48 year old patient who has been in your practice for 5 years. He has no significant medical history.

He shows up in your office today with excruciating pain on the right side. He says it has been hurting for about a week, starting with sensitivity to cold which then became a constant ache. He says he was unable to sleep last night.

Based on this history, what direction would you be headed with your diagnosis?

Dental pain

Pulpitis

Periodontal disease

Doesn't fit any of these categories

Getting to a Diagnosis



**ASKING THE RIGHT QUESTIONS AND
UNDERSTANDING THE ANSWERS**

The Next Step: Asking Questions

23

1. Now that you understand what the disease choices are, ask questions to pinpoint which symptoms this patient has.
2. Mentally categorize the answers into “bins” of diagnosis.
3. Decide which test you need to do based upon your tentative diagnosis.

Hang on through a few examples and this will start to make sense!

Remember from ODOM I....

Remember the mnemonic **OLD CART** to remember the seven attributes of pain?

Attribute	Sample question:
O nset	How long has it been bothering you? (ask “days? weeks? months?”)
L ocation	Can you take one finger and point to the area that hurts you?
D uration	How long does the pain last when it starts hurting? A few seconds or does it last for longer than a minute or so?
C haracter	Please describe your pain. Is it sharp, or is it dull and more of an ache? Has it changed over the course of time?
A ggravating/ A lleviating	What makes your pain worse? What makes it better?
R adiation	Does your pain spread out from the place that hurts you the most? If so, where?
T iming	Is your pain constant, or does it come and go? If it comes and goes, how frequent are your bouts of pain?

Back

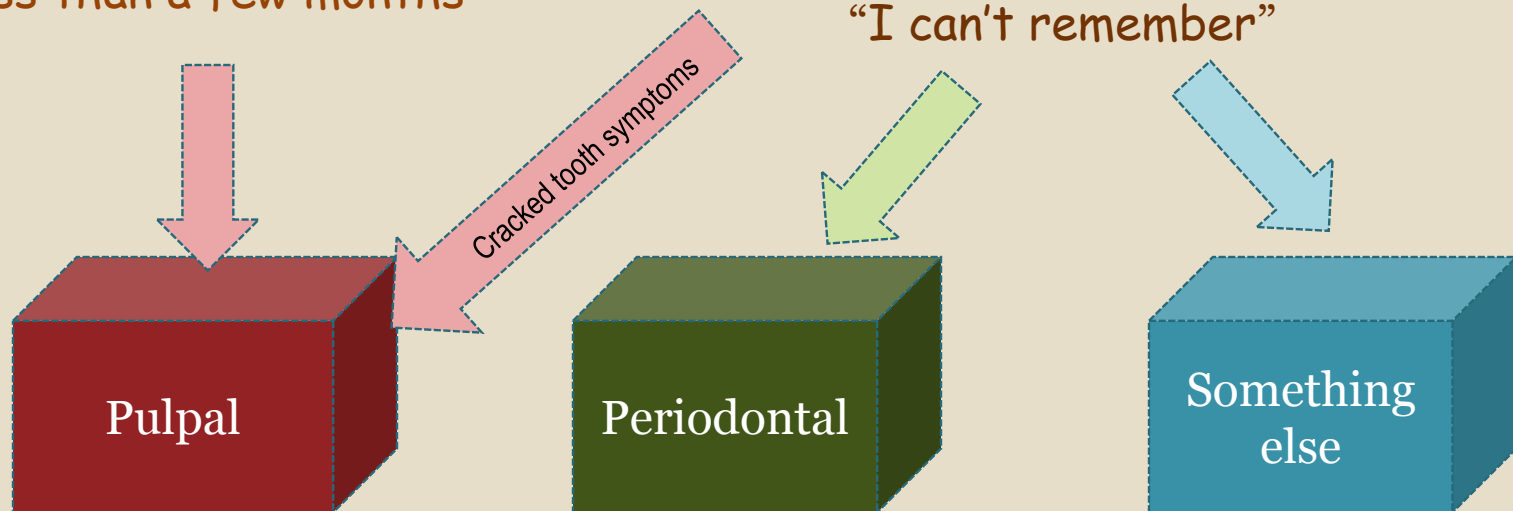
Onset: How Long Has It Been Hurting?

25

- *How long has this tooth been bothering you?*
- Remember, all of these are just general impressions, and very subjective, but usually:

"Less than a few months"

"More than a few months" or
"I can't remember"



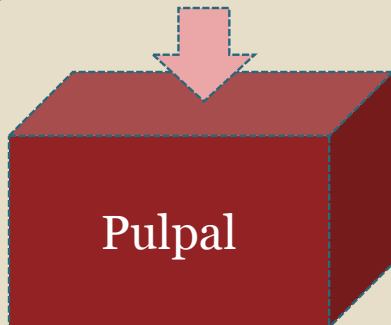
Onset: Follow-up Questions

26

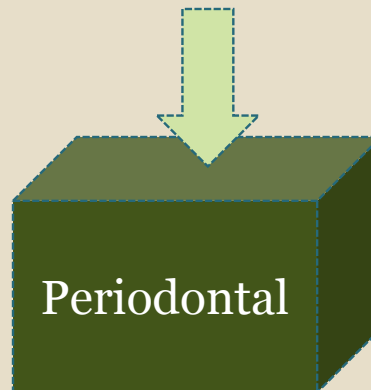
- *Have you **ever** had pain in this tooth before, and then had it get better?*
- Sometimes the tooth hurts a lot (irreversible pulpitis) then it dies and stops hurting, only to start abscessing 4-6 weeks later with a dull constant ache that hurts with biting (periapical periodontitis).
- Sometimes a cracked tooth will flare up, calm down, and flare up again.

"Yes, it's been coming and going for a long time" (cracked tooth)

"Yes, it hurt like crazy a month ago but then stopped" (irreversible pulpitis > necrotic)

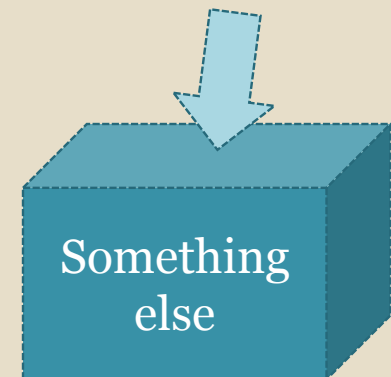


"Yes, it's swelled up before" (perio abscess)




"Yes, every time I exercise" (? angina)

"Yes, it hurts when I lean over" (sinusitis)



Location

27



- First, figure out **which tooth** is most likely to be the culprit. This is NOT as easy as it sounds!
- *Ask your patient to take one finger and point to the tooth that seems to be the problem.*
- But remember...
 - **Referred pain is common** (the patient is *sure* it's a "bottom tooth" but it's actually a maxillary tooth...).
 - **Pulps don't have proprioceptive nerves**, so it can be hard to pinpoint which tooth is involved if it's only a pulpal problem.
 - If pain has gone on for **several days**, it will **tend to generalize** for your patient, who will then just point to a side of his or her face.

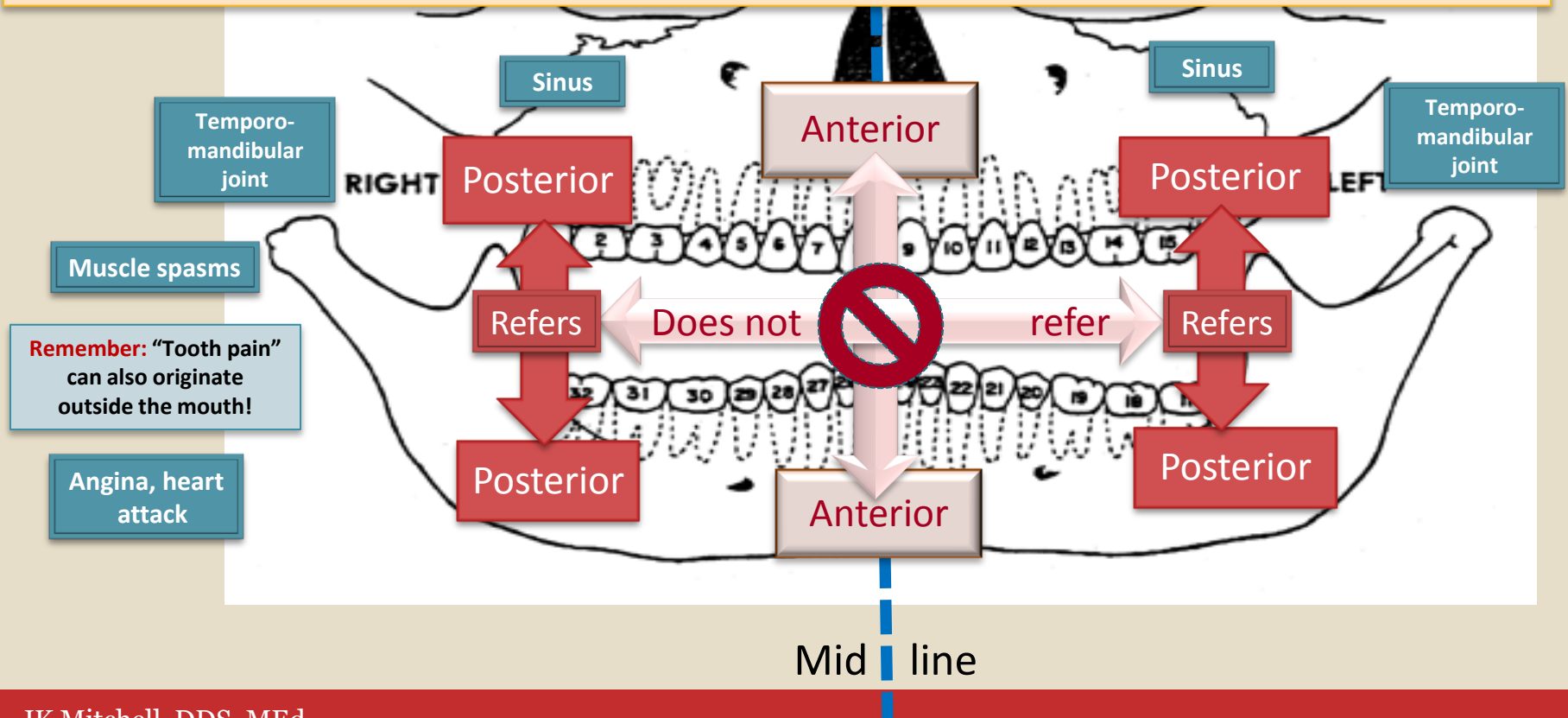
Location: Referred Pain

28



This is a busy slide, but it addresses an important concept. Basically, **pain does not *usually* refer across the midline or from maxillary to mandibular in the anterior.**


- If your patient says the pain is on one arch in the anterior, you don't need to test the opposite arch.
- If the pain is in the posterior, pain can refer - you need to test teeth in the opposite arch as well as the arch that your patient points to.



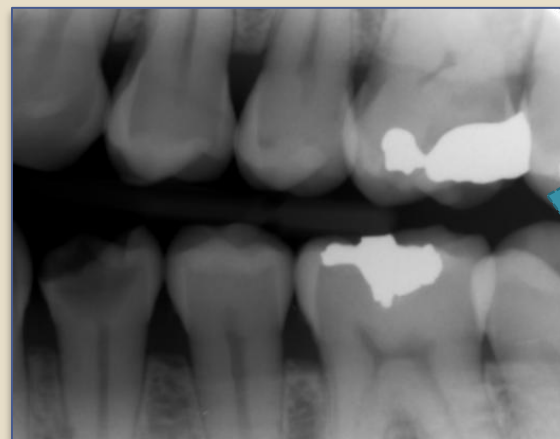


Location: Which Tooth is Most Likely Culprit?

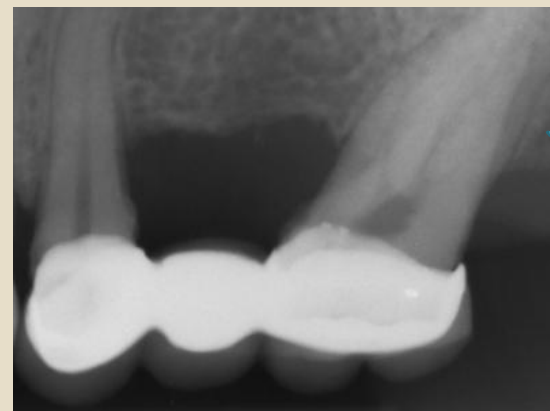29



- A tooth with deep caries and deep and/or extensive **restorations**.
- A tooth with a **crown** – it has about a 20% chance of pulp necrosis in a lifetime. Why?
 - ✦ Usually crowns are placed when **damage is too extensive** for direct restoration.
 - ✦ **Preparing a tooth for a crown is very damaging to the pulp**, since nearly all dentinal tubules are cut, causing damage to the underlying odontoblasts.



Note the deep caries on #21 and deep restoration with recurrent decay #14.



Either of these teeth could be a candidate for a non-vital pulp



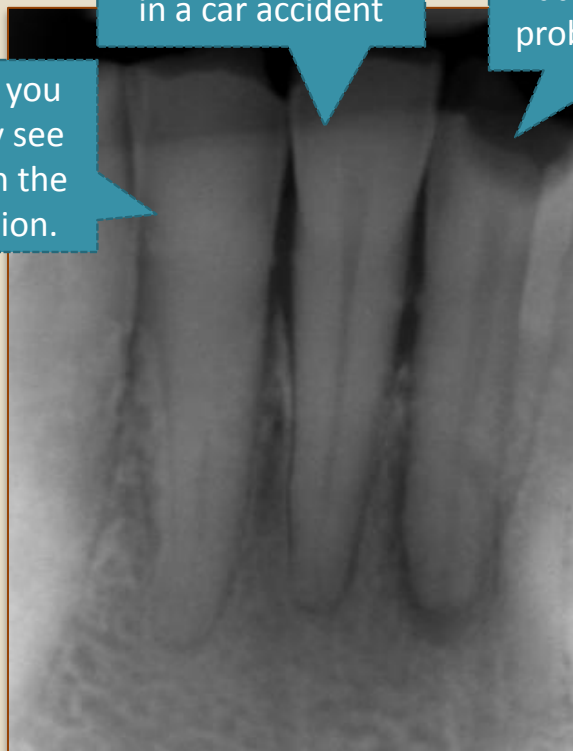
Location: Which Tooth is Most Likely Culprit?

30

Normal size pulp, but still suspect because it's next to a tooth broken in a car accident

Tooth with history of trauma. Note the periapical radiolucency- it's probably necrotic.

Note that you can barely see the pulp in the apical region.

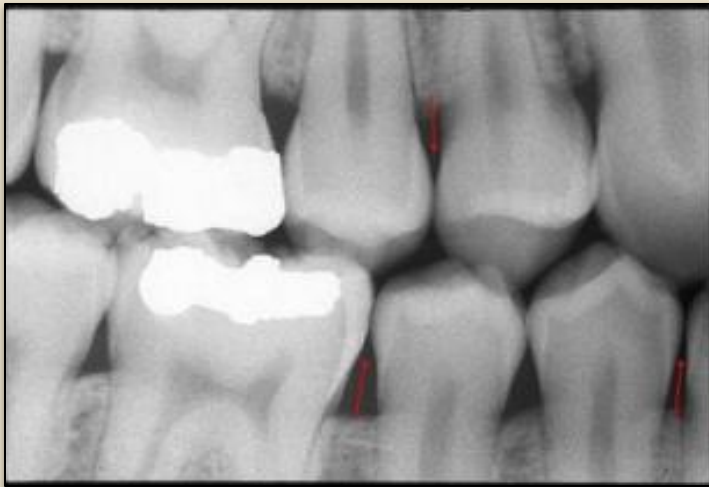


- For anterior teeth, look for **evidence of past trauma**:
 - ✦ A **chipped tooth**, or a tooth next to teeth that already have root canals.
 - ✦ A tooth that shows a **different color** from the others (past bleeding in the pulp chamber leaves a stain).
- Look at the **size of the pulp chambers**- any tooth with a chamber that is either **much larger or much smaller** than the rest is suspect.



Case 2: Michael's Radiograph

31



You pull Michael's records and look at his last set of bitewing radiographs on the right side. You ask him to point to the tooth that is bothering him. He points to #3. You note the large amalgams on #3 and #30.

Question 1. Which tooth is the most likely culprit? (click one)

#3

#4

#30

Can't tell

Question 2. Which teeth will you need to test? (click one)

All right teeth

All maxillary teeth

All right maxillary teeth

Duration

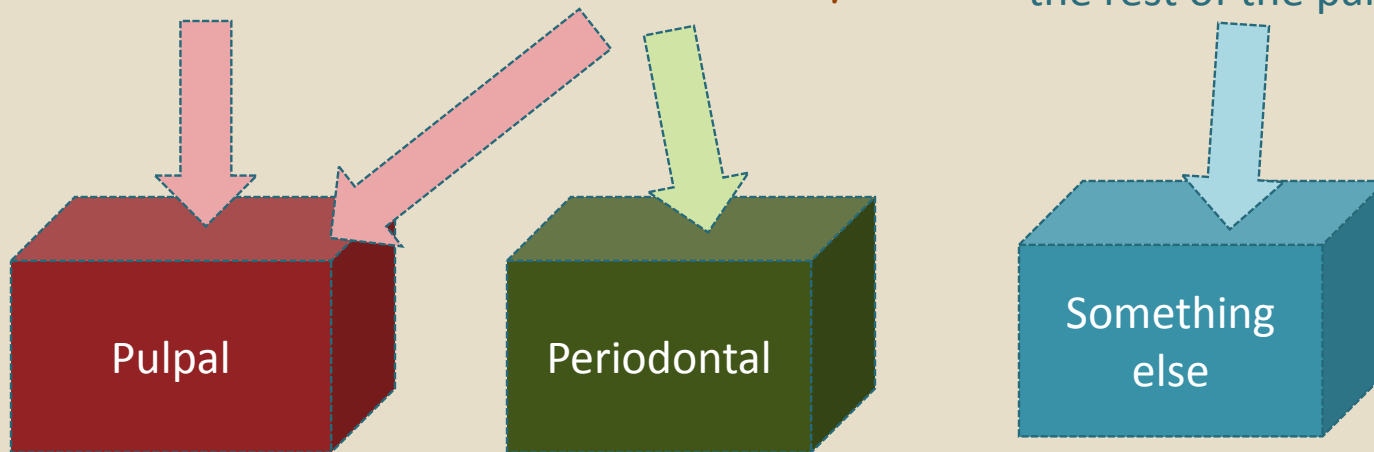
32

- Pain that is in response to a stimulus, particularly thermal:
 - ✦ Usually pain of **short duration**, less than 30 seconds indicates **reversible pulpitis**.
 - ✦ If it lasts **longer than 30 seconds** it usually indicates **irreversible pulpitis**.
- Dull constant pain is more likely to indicate periodontal or non-dental pain

"It hurts for like a minute after I take the cold off"

"It hurts constantly"

Any could fit, depending on the rest of the pain profile

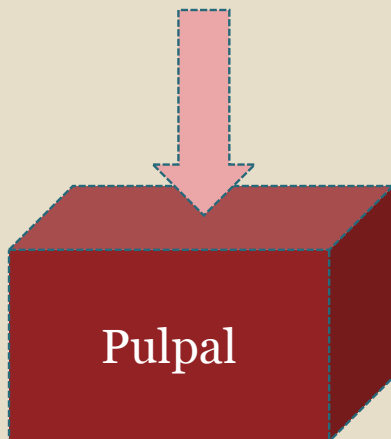


Character: Describe the Pain

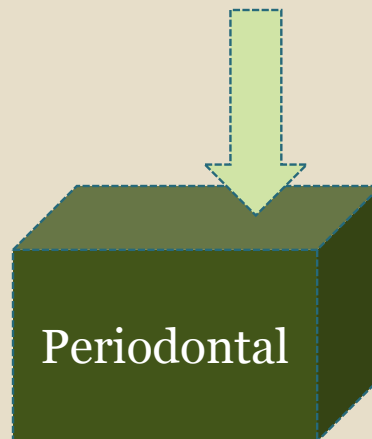
33

- *How would you describe the pain- sharp or dull?*
- Here's the classic profile:
 - Reversible pulpitis- Sharp, acute pain of short duration (A-delta fibers)
 - Irreversible pulpitis- Dull, constant ache (C-fibers)

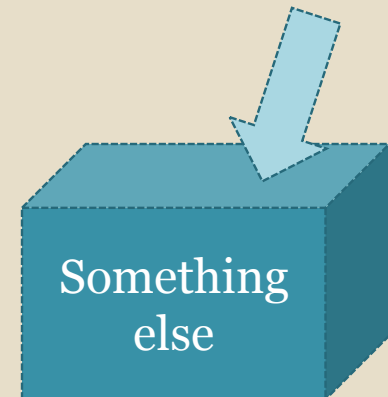
Short and sharp or
Dull and constant



"Constant dull ache"



Multiple profiles

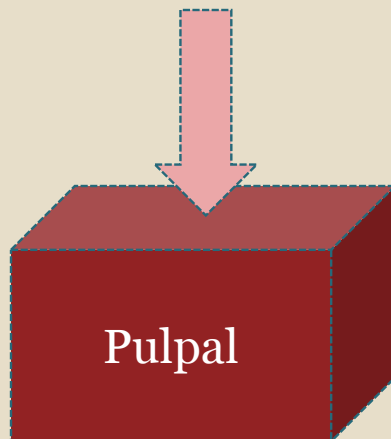


Character: Follow-up Questions

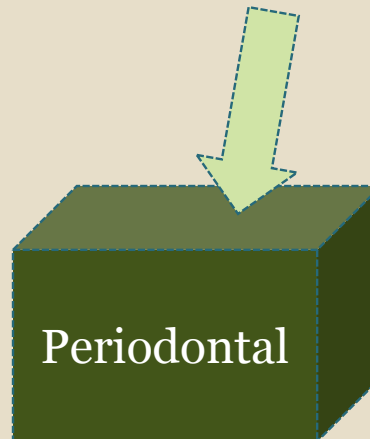
34

- *Is your pain staying the same or getting worse?*
- Usually pulpal pain will continue to get worse, while pain from other sources may stay the same.

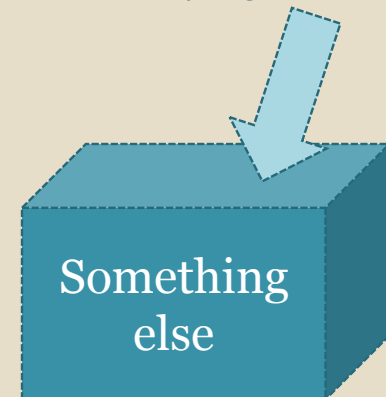
"Seems like it's getting worse and worse"



"Pretty much the same until this swelling started"



"It's getting worse and is radiating down my arm"
(Angina- Call 911!)"

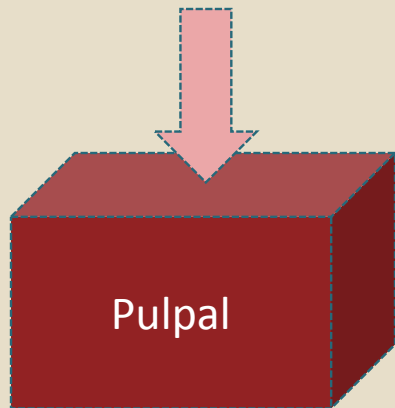


Aggravating Factors: Temperature

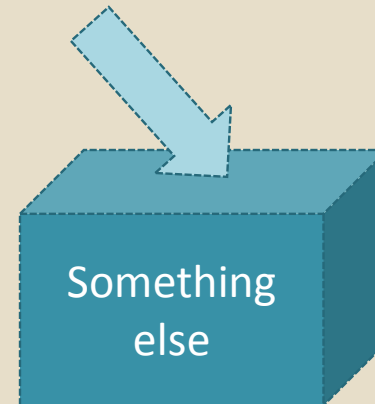
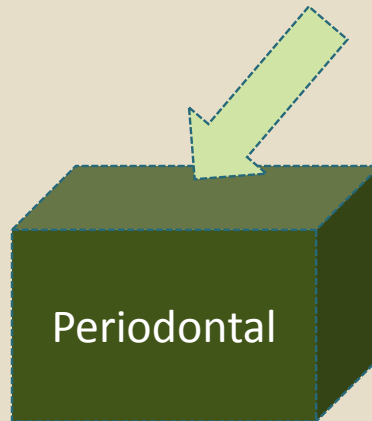
35

- *Does hot or cold start the pain or make it worse?*
 - Sensitivity to temperature generally means pulpal origin.
- **Cold sensitivity** is the most common symptom and the **most important** (other than the patient's history) in developing a diagnosis. We'll talk more about how to use cold as a diagnostic test.

"Yes, I can't put anything cold anywhere near it"



"Not really"



Aggravating Factors: Biting Pressure

36

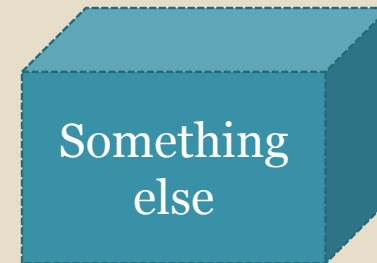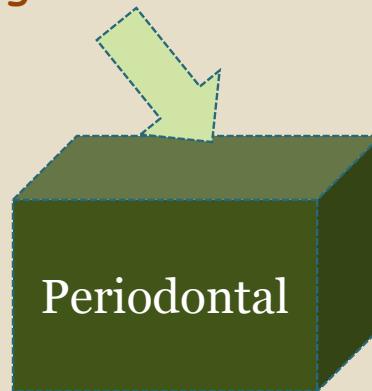
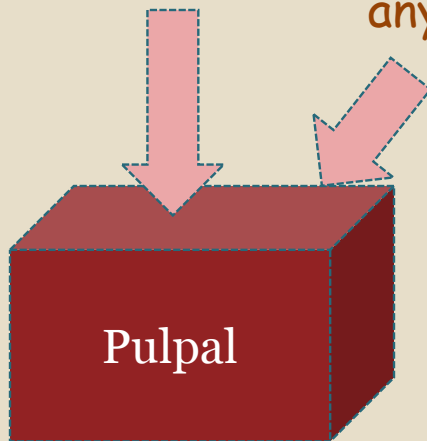
- Does it seem to hurt worse when you bite there?*

"Yes, sometimes there's a sharp pain, but not every time" (Think cracked tooth)

"No" (When just the pulp is involved)

"Yes, I can't chew anything over there"

(Either perio origin or a periapical abscess has formed)

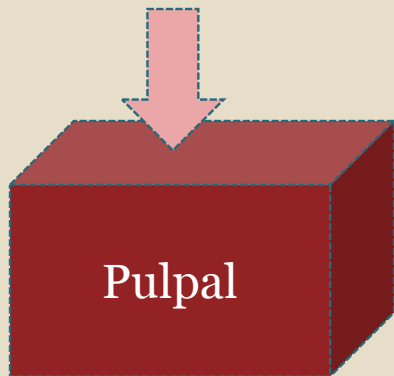


Alleviating Factors

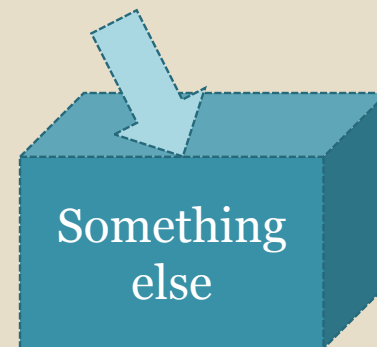
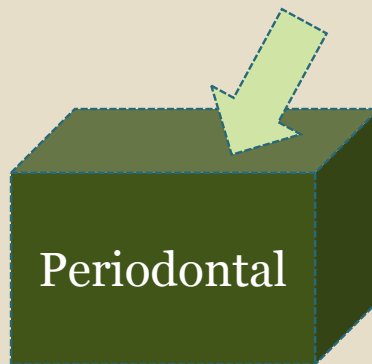
37

- *Does anything make it feel better?*
 - *If cold water alleviates the pain, think of irreversible pulpitis*
 - *If the pain is reasonably controlled by OTC pain meds, it probably isn't irreversible pulpitis.*

"Yes, I've been sipping ice water to help the pain"



"Yes, aspirin pretty much controls the pain"



More Questions....

38

The last two questions, concerning:

- ***Radiation***- *Does your pain spread out from the place that hurts you the most? If so, where?*
- ***Timing***-*Is your pain constant, or does it come and go? If it comes and goes, how frequent are your bouts of pain?*

Don't apply so much to routine dental diagnosis. If you are in the "something else" category, continue to collect the responses.

Study Guide: Symptoms

Attribute	Reversible Pulpitis	Irreversible Pulpitis	Periodontal Disease	Something Else
Onset	<ul style="list-style-type: none"> Recent- days to weeks May have cyclical history of flare-ups if cracked tooth 	Fairly recent- days to several weeks, and worsening perceptibly.	Hard to determine- may be months, with a recent start for acute pain	<p>If the symptoms just aren't falling into any of these patterns, a little red flag should come up and you should start considering all the other sources of pain in the head and neck region.</p>
Location	Patient report is unreliable since no proprioception in pulp. Suspect teeth with caries, recent restoration, previous large restoration or crown. Test all teeth in same quad on ant, same and opposing in posterior.		Acute area may be localized but usually other areas of disease in the mouth	
Duration	If brought on by stimulus (ie cold), usually short duration (<30 sec)	If brought on by stimulus (ie cold), usually lingering duration (>30 sec)	Usually a more constant type of pain	
Character	Generally a sharp, pricking sensation	May be dull to acute, even incapacitating. Generally more of a deep, dull, throbbing ache. Slower to start, slower to dissipate	Generally a dull, constant ache	
Aggravating factors	Usually sensitive to cold. Usually not sensitive to biting pressure except if tooth exhibits cracked tooth syndrome	May be sensitive to cold or hot, biting pressure	Sensitive to biting pressure	
Alleviating factors	Usually none	Cold or ice water may alleviate. OTC meds may help, but not usually.	Warm salt water rinses may alleviate. OTC meds help unless acute abscess.	

Back

Make a Tentative Diagnosis

40

- By now you will have an idea of whether your patient's pain is more likely to be **pulpal** or **periodontal** in origin, or whether its pattern **doesn't fit either**, in which case you need to think about etiologies other than dental origin.
- You will do many of the same tests no matter what your working diagnosis, but you are constantly evaluating the results of your tests to see if they fit your tentative diagnosis.

Case 3: Michael's Answers

41

- You ask all these questions, and get the following answers:
 - It's been hurting for a few weeks, starting as acute sensitivity to cold.
 - It doesn't really hurt when I bite down.
 - It has been getting progressively worse and worse, to the point where it is now interfering with my sleep.

What is your working diagnosis? (click one)

Reversible
Pulpitis

Irreversible
Pulpitis

Periodontal
abscess

Now what do you need to do to get a final diagnosis?

Diagnostic Testing



- WHICH TESTS TO DO AND WHEN
- HOW TO DO THE TESTS
- WHAT THE ANSWERS MEAN

Testing Suspect Teeth

42

For all the teeth in the quadrant that your patient has identified as troublesome:

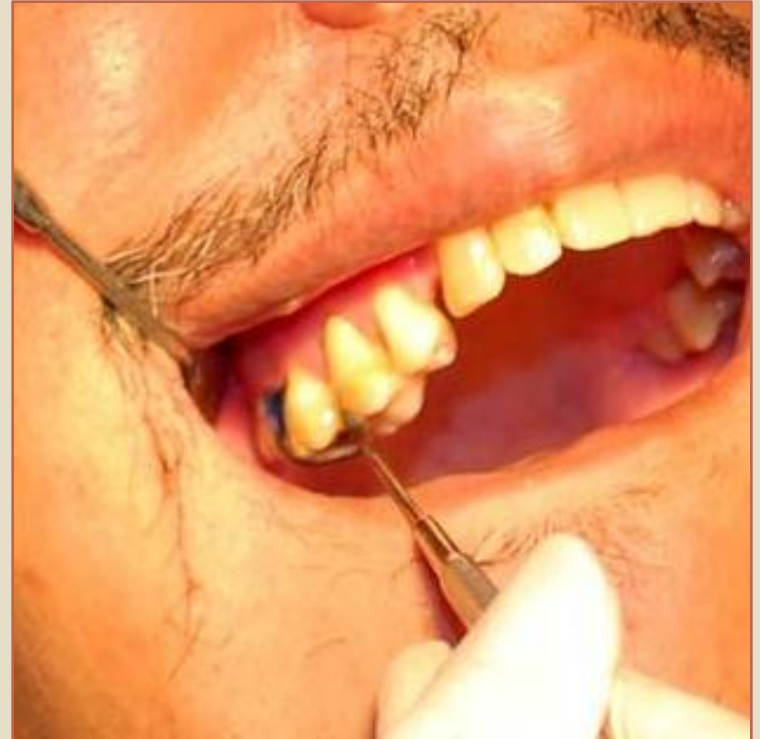- **Percuss** - gently tap on each tooth along the long axis (straight down the occlusal) and ask if any of them feel different than the others.
- **Palpate** - gently roll your finger along the area over the root tips and ask if any areas are particularly sensitive.
- Perform a **cold test** - vital pulps can feel cold, and how long the pain resulting from cold stimulation lasts is critical.
- Perform **periodontal probing** - you'll learn the specifics in Perio class.
- ***Do NOT take radiographs until you have eliminated all the causes of pain that mean a vital pulp with either a normal or reversible pulpitis diagnosis from your list of working diagnoses!!!***

Testing: Percussion



43

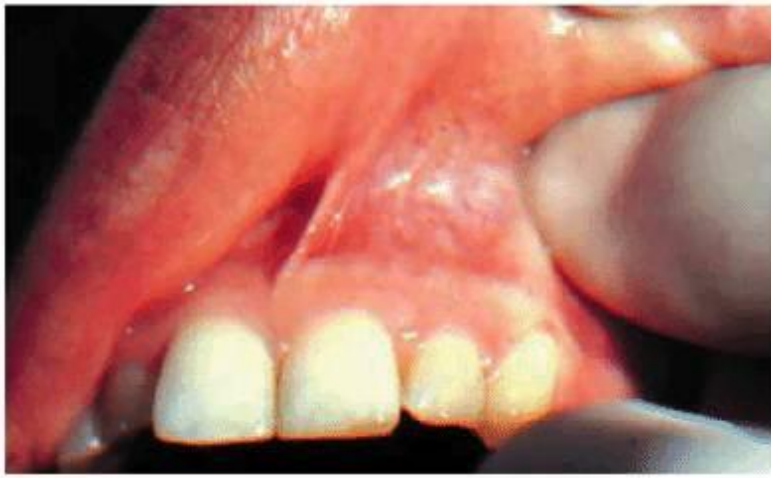- Percussion is a big name for a simple procedure. You're just tapping a tooth into its socket. Any **inflammation in the socket will cause pain** with this maneuver.
- ***So start gently!*** Barely touch the tooth, then go back and tap it more firmly if no response to gentle pressure.
- Remember: inflammation in the periodontal ligament can be from pulpal disease or periodontal disease.



Testing: Palpation



44



- When you're palpating, you're feeling for any **sensitivity to pressure over the bone** (apical tenderness).
- Roll the **pad of your index finger over the bone** in the quadrant.
- Ask your patient to tell you if anything is sensitive.
- A **positive response may mean inflammation on the inside of the bone**, usually from pulpal necrosis.

Cold Testing



45

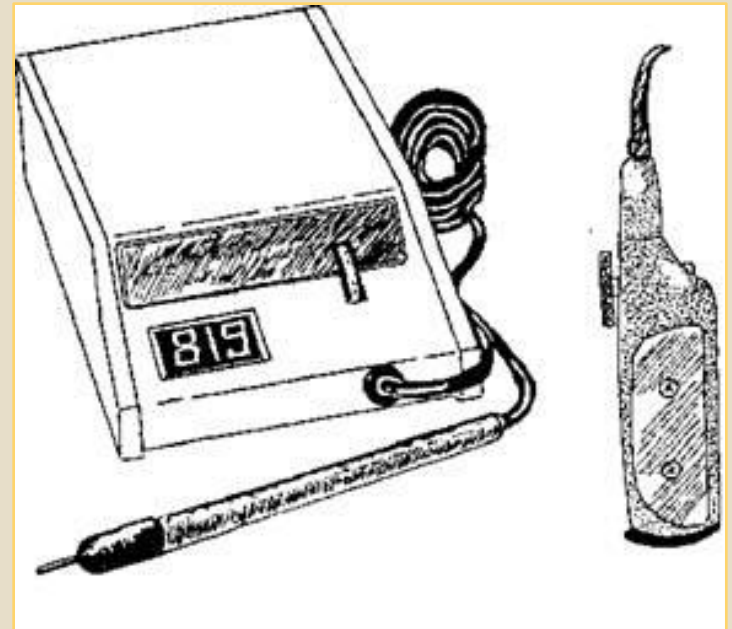


Endo-Ice®

Skin refrigerant in a can

How to use: Spray a drop into a cup, dip a cotton pellet, and touch the tooth.

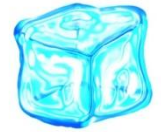
Most reliable- first choice



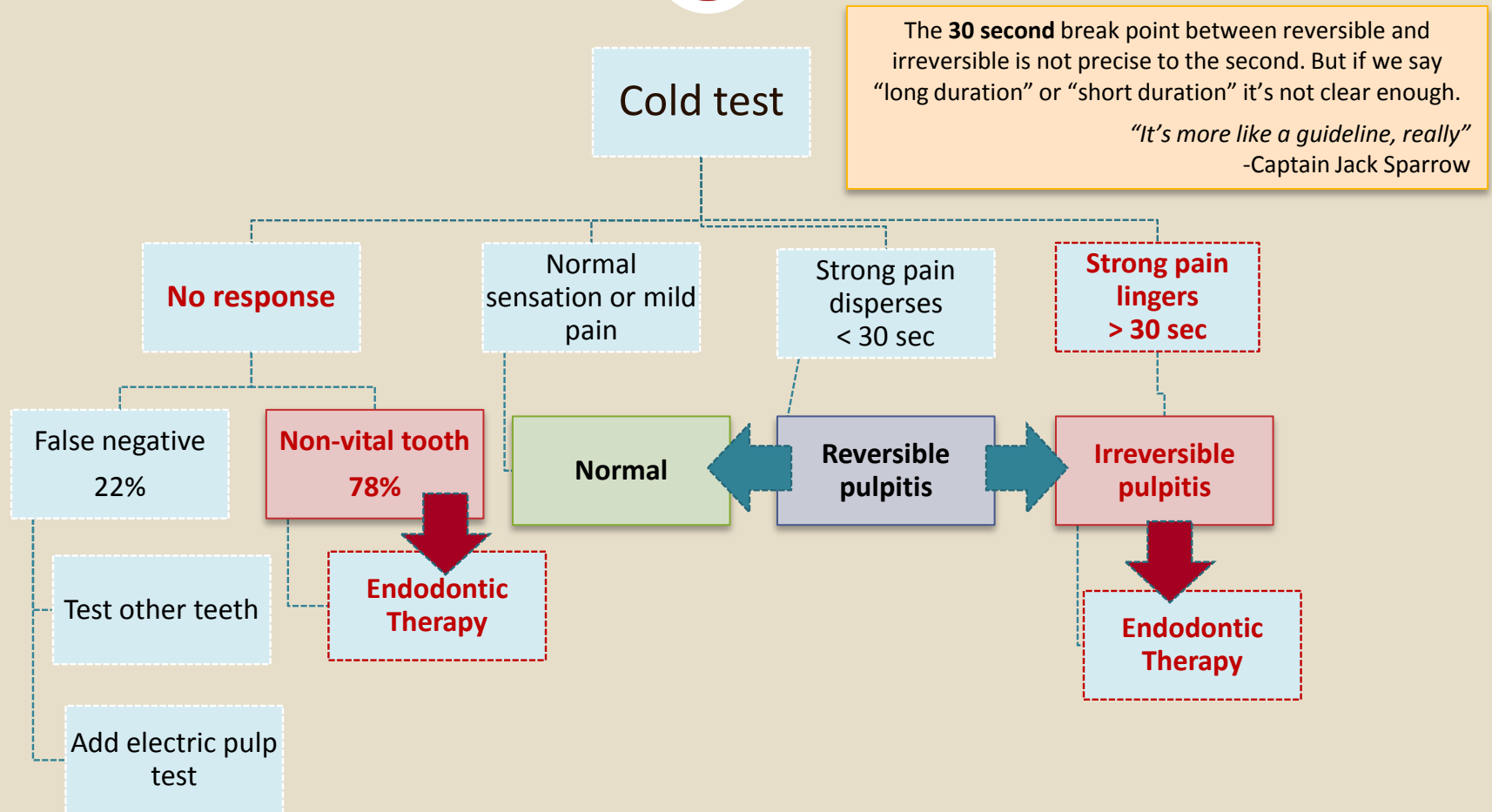
Electric Pulp Tester

Sometimes can help confirm

Cold Testing: What does it mean?



46

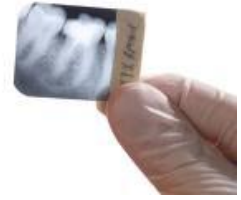

► Weisleder R et al “The validity of pulp testing: A clinical study”
JADA 140(8) 1013-1017 (2009)

Study Guide: Testing for Dental Pain

If you think its:	Do these tests:	And the answers mean:
Pulpal Pain: Dentinal Usually sharp, short, may have sensitivity to cold.	<ul style="list-style-type: none"> • Puff air on exposed dentin • Gently scratch dentin with explorer • Test for cracks 	If your action duplicates the pain, you generally have a diagnosis
Pulpal Pain: Pulpitis	Consider tests above	Rule out dentinal pain
	Test with cold (electric pulp test)	Sensitive < 30 sec duration: Reversible Sensitive > 30 sec duration: Irreversible No sensation: necrotic or false negative
	Percuss/palpate	Rule out periodontal involvement
Pulpal Pain: Periapical or Periodontal Involvement	Percuss/palpate	Ensure correct tooth diagnosis Evaluate level of perio involvement
	Periodontal probing	Rule out periodontal disease origin
	Take periapical radiograph	Evaluate location/bone destruction
Periodontal Pain	Periodontal probing	Locate offending perio pocket
	Percuss/palpate	Confirm location of inflammation
	Take periapical radiograph	Evaluate bone destruction

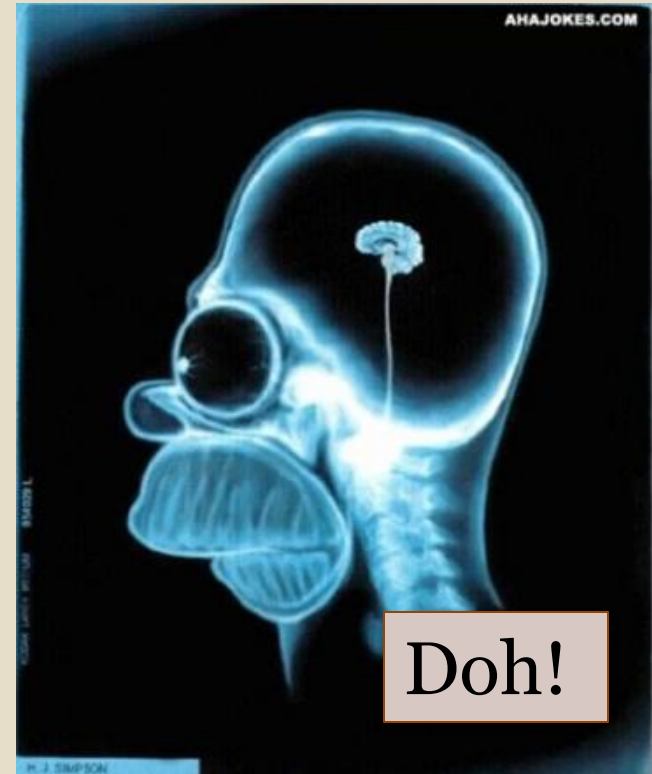
Radiographs



48

Before you **irradiate** a patient (not a totally harmless thing to do...), do a history and clinical examination!

- Radiographs are an important part of the diagnostic process, but they should be done only when **required to make or confirm your diagnosis**.
- A radiograph is **usually not needed when the working diagnosis is**:
 - **Normal pulp**- dentin hypersensitivity, for example
 - **Early or Reversible Pulpitis**
- Radiographs **cannot tell you anything about the state of the pulp**. You won't see anything on an x-ray until there is extensive bone loss at the apex.
- Otherwise, if you are diagnosing a serious candidate for pulpal or periapical pathosis, if you need a radiograph to make or confirm your diagnosis, take it!



Case 4: Michael's Test Results

49

- Based on the chart, you decided to cold test, percuss, and palpate all teeth on Michael's right side. Here are the results:
 - **Cold test.** All teeth on his right side are within normal limits except for #30, which is acutely sensitive to cold, and the pain lasts longer than 30 seconds.
 - **Percussion/palpation.** No sensitivity to percussion or palpation on his right side except #30, which is somewhat sensitive to percussion.
 - **Periodontal probing.** No periodontal pockets >3 mm

Question 1. Do you *need* a radiograph to make a reasonable diagnosis? (click one)

Yes

No

Question 2. What's your best diagnosis now? (click one)

Reversible
Pulpitis

Irreversible
Pulpitis

Periapical
Abscess

Learning Objectives

50

- 1 Explain the steps in the pain diagnosis process
- 2 Identify the possible sources of orofacial pain
- 3 Relate the three types of nerve fibers found in pulp and how their responses are critical in diagnosing pain
- 4 Interpret from symptoms and radiographic appearance if pain is likely to be pulpal or periodontal in origin.
- 5 List which questions to ask from the mnemonic OLD CARTS, including follow-up questions.
- 6 Associate which symptoms relate to common pain diagnoses
- 7 Relate test results to common pulp, periodontal, or other diagnoses

Great work! You've learned a lot!



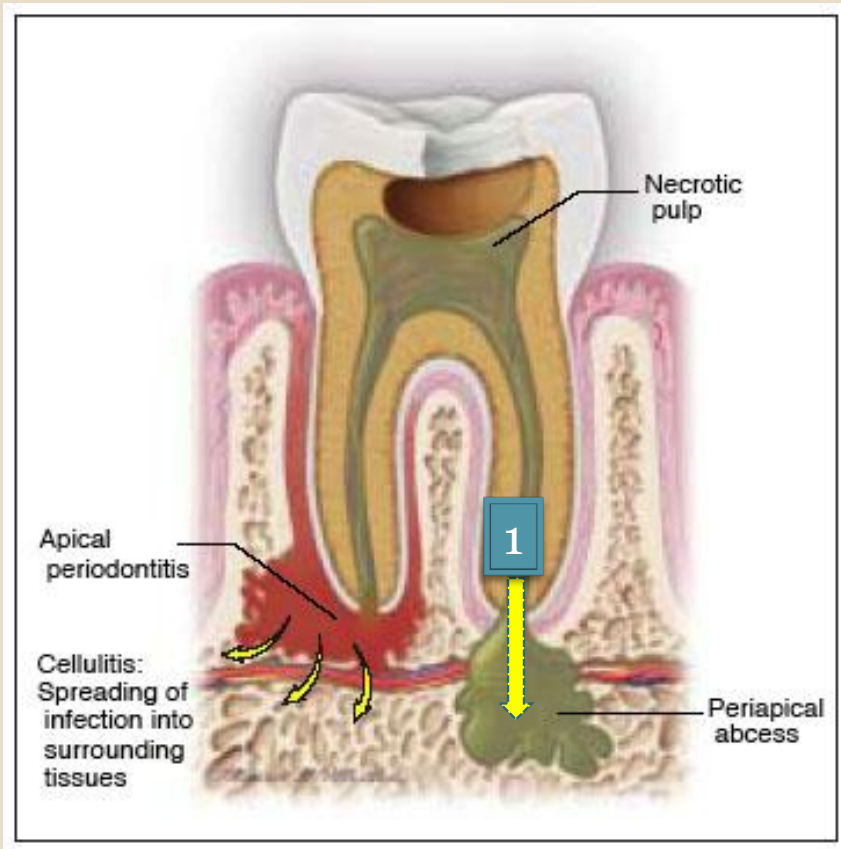
Chambord
Castle of Francoise I

STOP

Pulpal Origin: Periapical Involvement

21

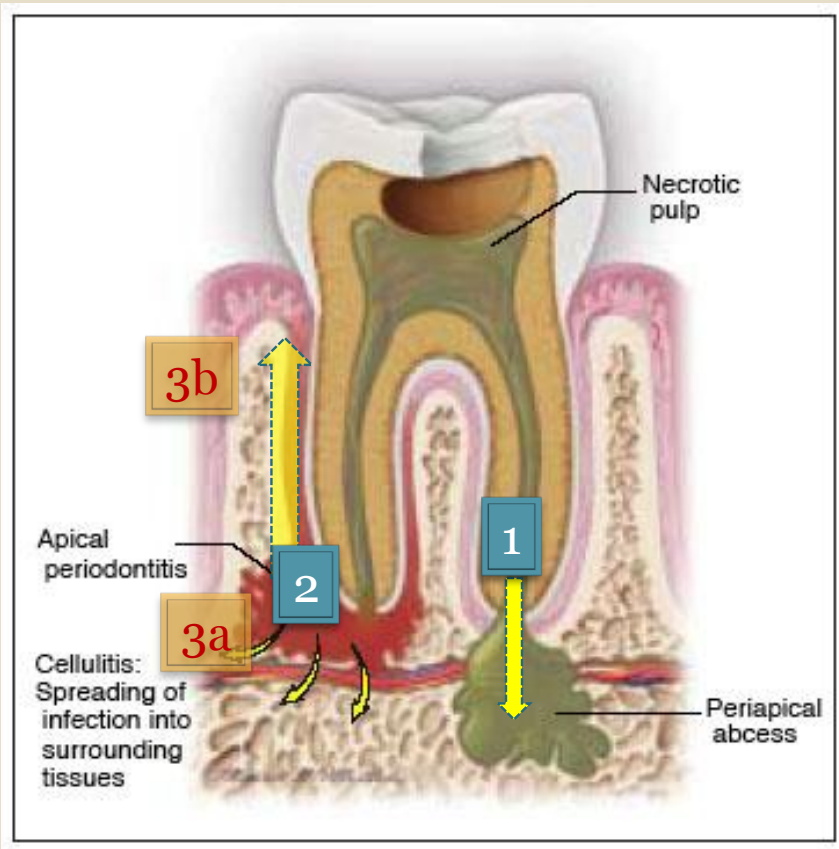
1. As the by-products of pulp breakdown **exit the end of the root** (the apex) into the bone, the tooth becomes very sore to touch, and it aches.



Back

Pulpal Origin: Periapical Involvement

21



1. As the by-products of pulp breakdown **exit the end of the root** (the apex) into the bone, the tooth becomes very sore to touch, and it aches.
2. At that point, the **periodontal tissue can become infected** because of the necrotic pulp.
3. The pressure of this infected pocket seeks a **weak spot** to break through:
 - a. Through the bone into **soft tissue**, like the cheek, or through to the **gum** next to the end of the root (most common).
 - b. Through the **periodontal ligament**.

Back

You Answered “Dentinal Pain”

60



- Probably not. The pain has lasted too long and is getting progressively worse.
- Dentinal pain is usually provoked by something in particular, like air, or tooth brushing.
- Try again!

Home

You Answered “Pulpitis”

61



- **Good instincts!**
- Michael's pain has lasted too long for dentinal pain and is getting progressively worse, both symptoms of pulpitis.
- Pain this severe is more likely to be pulpal than periodontal.

Home

You Answered “Doesn’t fit”

62



- Possible, but not the most likely guess. Pain this severe is likely to be of dental origin.
- Try again!

Home

You Answered “Periodontal Disease”

63



- Possible, but not the most likely guess. Pain this severe is more likely to be pulpal than periodontal.
- Try again!

Home

You Answered “Yes”



- You are correct, technically. There has to be significant bone destruction to show up on a radiograph, and this almost always means that the tooth is already necrotic and probably has been for awhile. If the tooth is still vital, no matter how inflamed, a radiograph will probably not show you anything.
- *But* this situation is complicated! This tooth clearly has a significant pulpal disease, long past dentinal pain or reversible pulpitis.
- Pulpal disease is complex, and as part of making a final diagnosis, which includes ruling out other problems you might see on radiograph, *you should take a radiograph of #3, #30.*

You Answered “No”



- You are correct, but understanding why is complicated!
- There has to be significant bone destruction to show up on a radiograph, and this almost always means that the tooth has been necrotic for some time. If the tooth is still vital, no matter how inflamed, a radiograph will probably not show you anything.
- But this tooth clearly has significant pulpal disease, long past dentinal pain or reversible pulpitis.
- Pulpal disease is complex, and as part of making a final diagnosis, which includes ruling out other problems you might see on radiograph, **you should take a radiograph of #3, #30.**

You Answered “Reversible Pulpitis”



- Based on the results, there is probably a better diagnosis.
- Try again!



Home

You Answered “Irreversible Pulpitis”



You are correct!

- The cold test found the correct tooth and, since the pain lasted longer than 30 seconds, confirmed your tentative diagnosis of irreversible pulpitis.
- Since there is no sensitivity to biting, percussion, or palpation, there is no indication of periapical inflammation.
- Since there are no significant periodontal pockets, it is not a periodontal abscess.
- Good diagnosis, Doctor!

Home

You Answered “Periodontal Abscess”



- Probably not, since there are no significant periodontal pockets.
- Try again!

A teal-colored triangle pointing upwards, located in the bottom right corner of the slide. The word "Home" is written in white text inside the triangle.

Home

You Answered “Reversible Pulpitis”

69

- Probably not. There are several symptoms that are not consistent with that diagnosis.
- Try again!

Home

You Answered “Irreversible Pulpitis”

70



Good working diagnosis!

- The acute sensitivity to cold and the fact that Michael’s pain is now keeping him up at night are good indicators that his problem is past the reversible stage and into irreversible pulpitis territory.
- Nice work!

Home

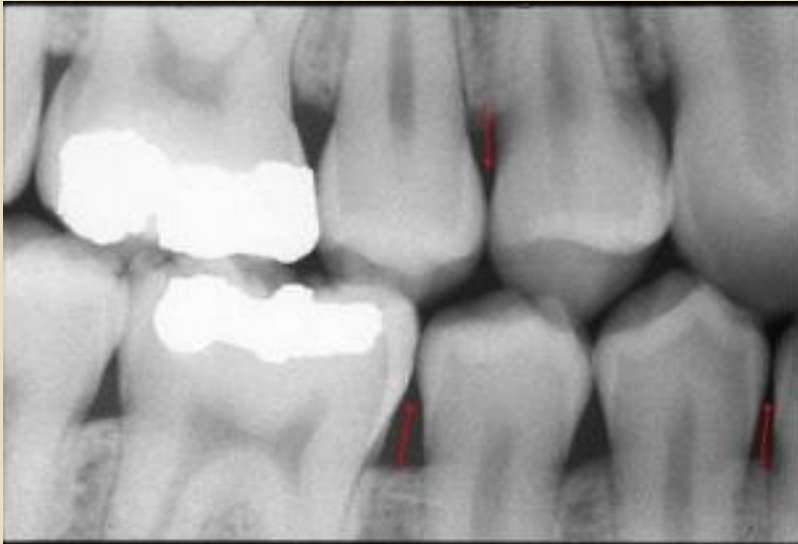
You Answered “Periodontal Abscess”



- Probably not. The tooth is not sensitive to biting pressure, and there are no significant probing depths.
- Try again!

Home

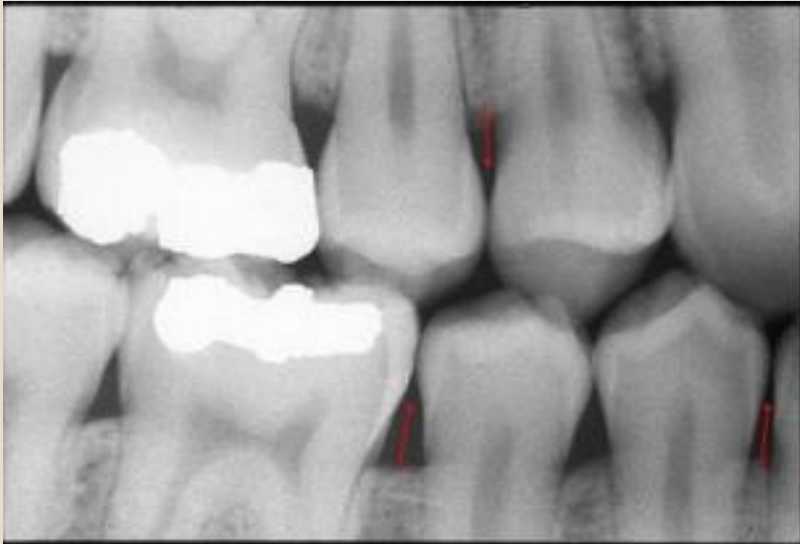
You Answered #3



- Reasonable guess. There is a large restoration on it that looks like it was close to the pulp.
- Just don't get too stuck on that tooth...keep your mind open for other possibilities.
- Are there other good answers?

Home

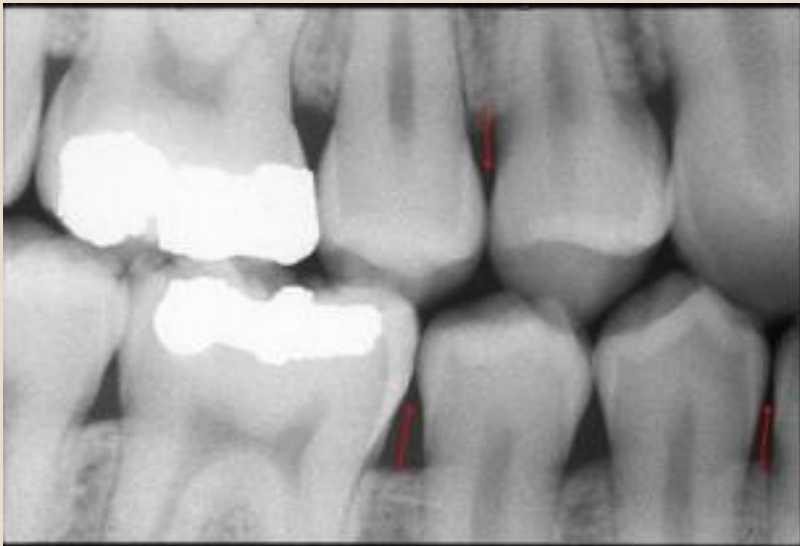
You Answered #4



- Probably not. There is no restoration on this tooth, and it is too far back in the mouth to have been traumatized.
- There are more likely answers...try again!

Home

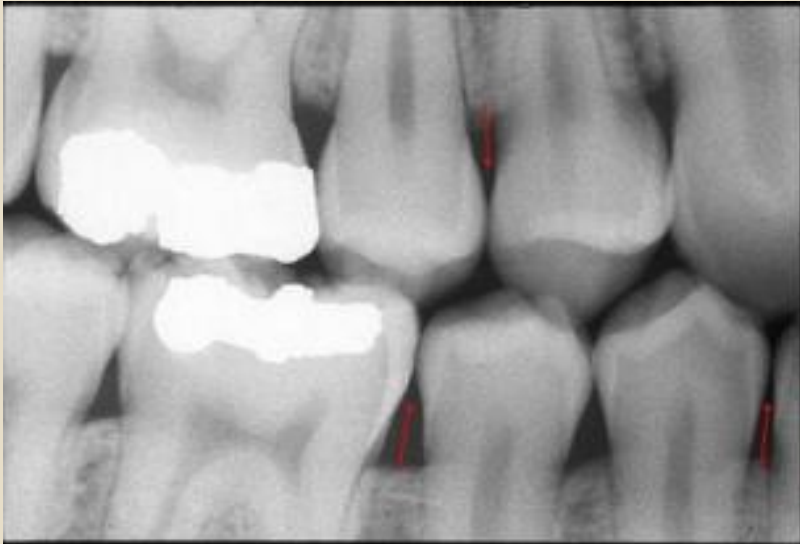
You Answered #30



- **Reasonable guess.** There is a large restoration on it that looks like it was close to the pulp.
- Just don't get too stuck on that tooth...keep your mind open for other possibilities.
- Are there other good answers?

Home

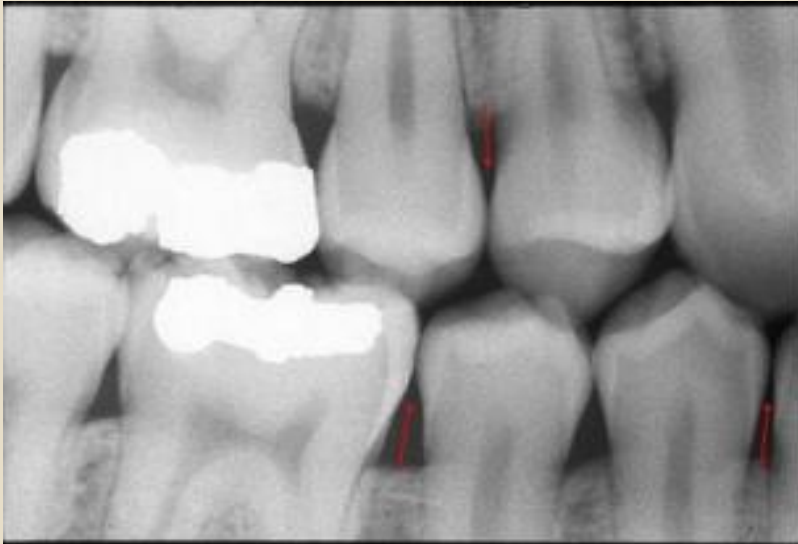
You Answered “Can’t tell”



- Very true, there’s not enough information to be *sure* which tooth is the most likely.
- But it’s OK to at least have a tooth or two in mind as the most likely cause.
- Try again!

Home

You Answered “All right teeth”

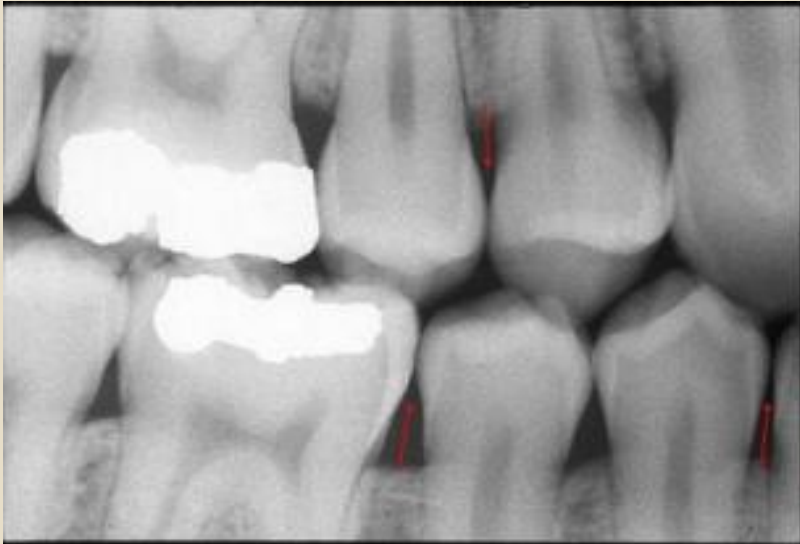


Correct!

- Since pain can refer from maxillary to mandibular in the posterior, you'll need to test both maxillary and mandibular teeth.
- Nice work!

Home

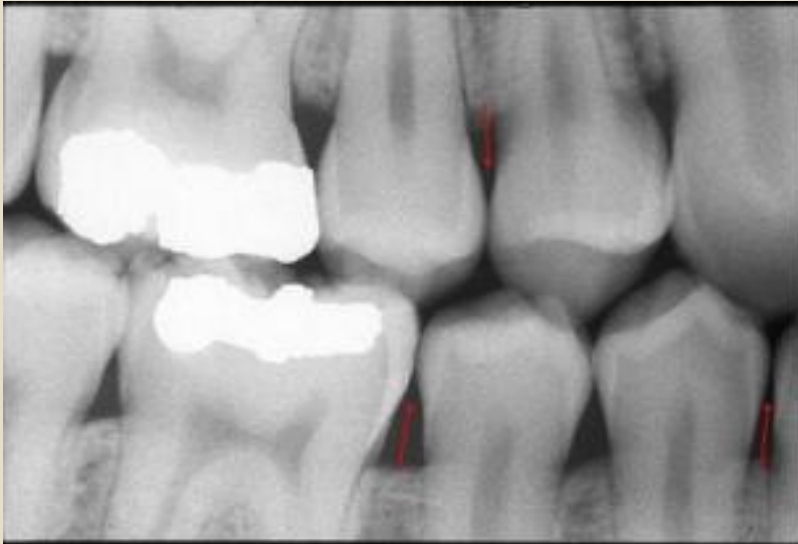
You Answered “All maxillary teeth”



- No, it is very unlikely that pain felt on the right side is caused by a tooth on the left side.
- Try again!

Home

You Answered “All right maxillary teeth”



- That’s a good way to start, but referred pain is common enough that you probably shouldn’t stop there.
- Try again!

Home

