

5. REASSESSMENT PHASE

Treatment Planning

Learning Objectives

1

1. List the requirements for a D0003 signoff in clinic (Beyond *just* finishing the operative treatment!)
2. Explain why an endodontically treated tooth is the exception to the phasing guidelines, and list the locations on a tooth where bacteria can leak. List the best restorative options for anterior and posterior teeth.
3. For each checklist, be able to explain why each item is evaluated prior to moving to Phase 3.

OK, now we have taken care of the patient's immediate problems.

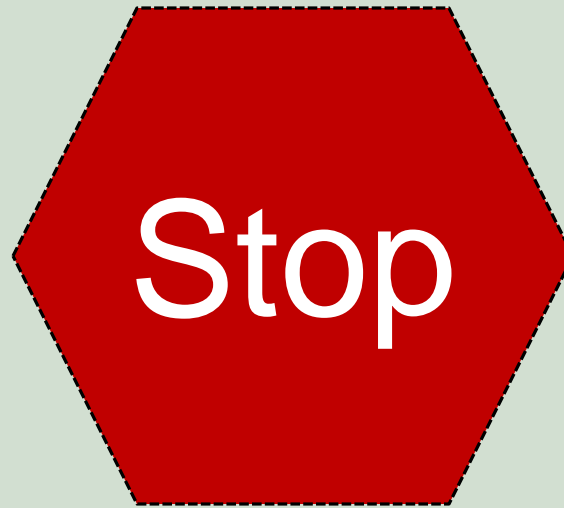We've done all the procedures that were planned to control disease.

Time to move on the **big stuff**, right?

The Fixed Pros, the Removable Pros, the Esthetic fun stuff!

Not so fast.....

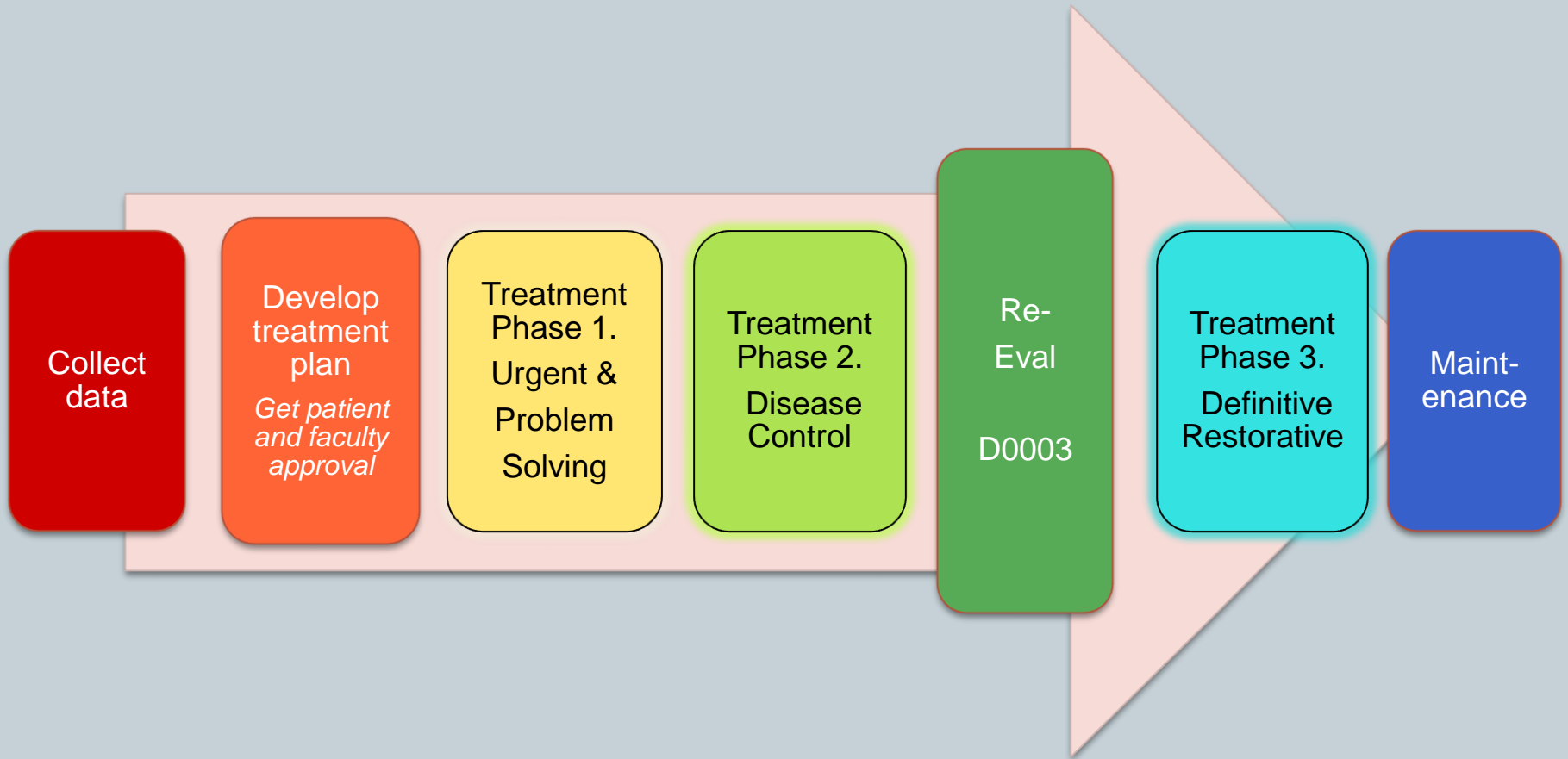
It's time to



and see if the patient is *really* ready!

Treatment Planning Process:

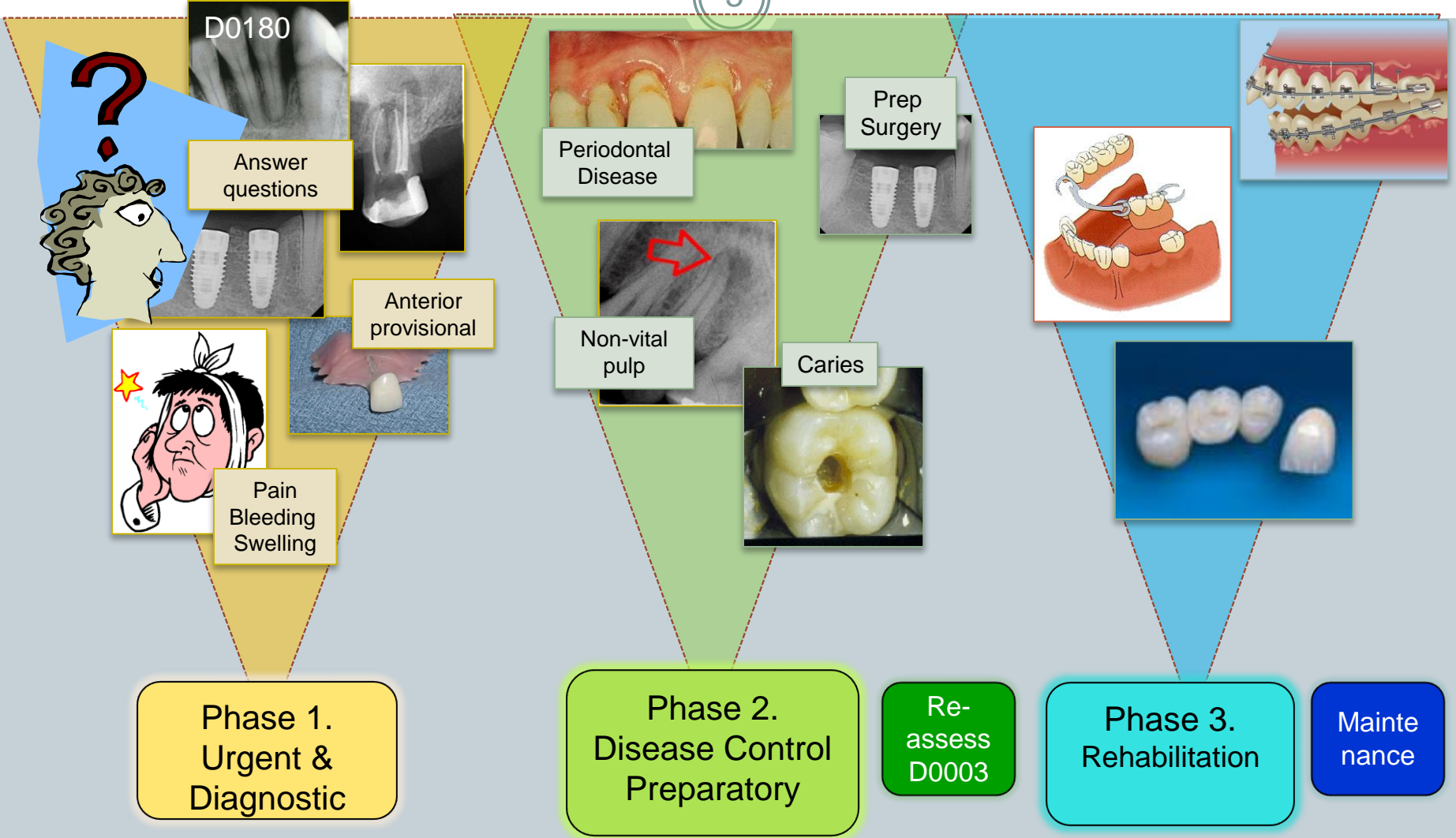
4



Overview of Phases

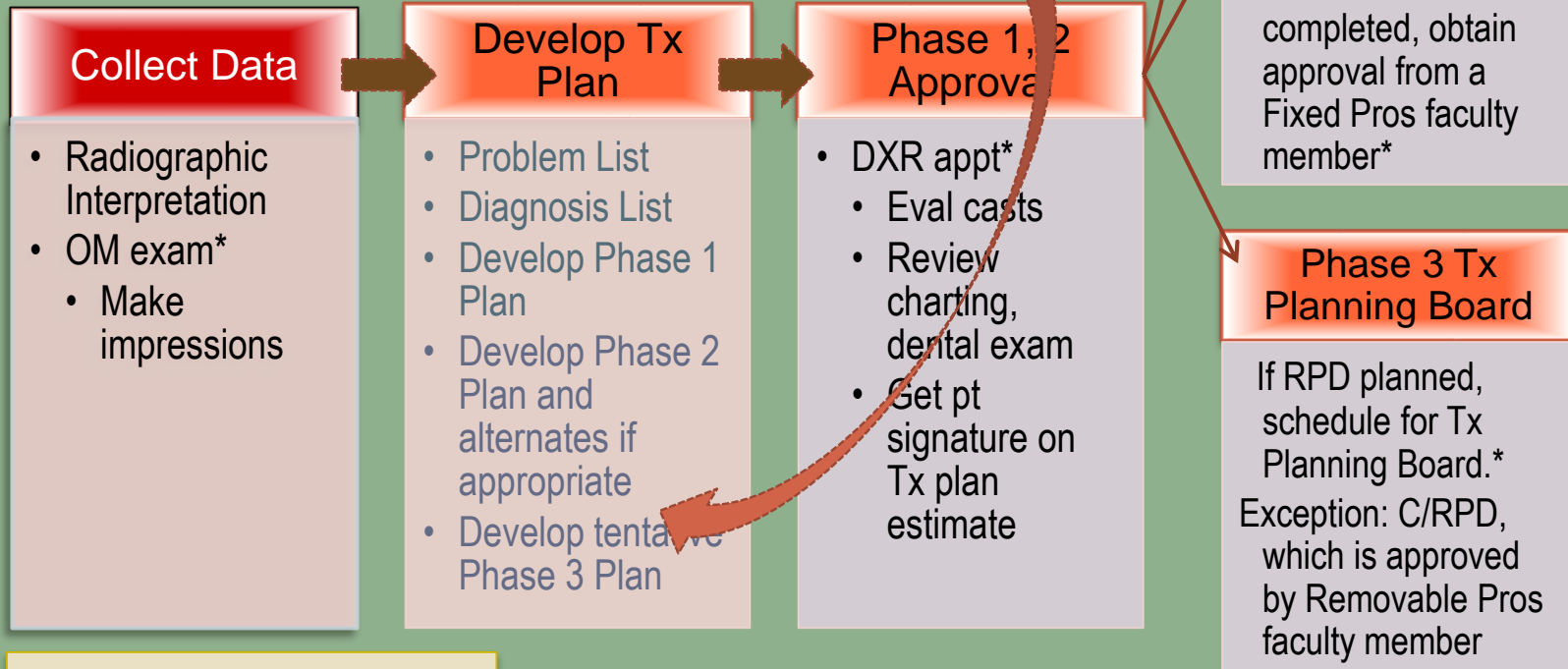
Re-eval

5



Data Collection → Tx Plan

Re-evaluation is called “Department Case Complete” or a **D0003**, usually Operative & Perio. It always happens between Phase 2 and 3



*=Pt present

Gray= work done between appts

We know what we're concerned about:

Re-
eval

7

- Back to our three diseases!
 - Have we gotten control of the disease processes?
 - Can we move on to our tentatively planned Phase 3 care and be reasonably confident that it will be predictably successful for the patient?
 - Remember- even if you do perfect dentistry, without the disease processes under control, you are just making jewelry for a diseased patient, not being a doctor!



So we stop and do an evaluation of the outcomes of all the previous treatments and reassess the prognosis of planned phase 3 treatment.

Overview of Reassessment

Re-
eval

8

Generally, treatment in Phase 3 should not start until Reassessment goals are met. It *may not even be ethical* to continue with treatment if you know that active disease has not been controlled to a level that can make Phase 3 care predictably successful. So back to our three diseases:


- 1. Oral Cancer** and other oral diseases. If you noted a lesion, follow up to make sure it resolved. If not after 2-4 weeks, it needs to be in a jar so the pathologist can look at it. If you sent a consult, you need to have a response, follow up on the results, and ensure the patient has stabilized.
- 2. Periodontal disease.** After the correct time to allow for healing, the charting is done again to evaluate if the problem areas are resolved. By this time you have been able to evaluate the patient's plaque control over time and determine if they can control their disease successfully.
- 3. Caries.** Because caries is relatively slow, it's hard to be sure that the disease is controlled until several *years* have passed-that's why 36 months is the past evaluation time frame in caries risk!- but you're not going to make your patient wait that long. But you can talk to your patient and get a sense for whether they are on board or not.

But it's called....

Re-
eval

9

- The **code we use in axiUm** to make sure this step is done correctly is a **D0003**, which is called an “**Department Case Complete.**”
- *This is a terrible name...* it makes it sound like the only question is *So is all the Operative treatment finished?*
- Instead, it's just a code....and a name for the re-eval process that we're going to describe here. You will use it in other areas (like Perio) when your treatment plan has reached the end of the active phase.



But it is certainly **not** an add-on at the end of an appointment, as in “Oh, by the way, can you sign off my Operative Department Case Complete since this is the last restoration this patient needs?” *Nope...*

Reassessment Phase Goals

Re-
eval

10

- Go back to your original problem list (another reason not to pack it with a lot of extraneous junk “just so I don’t miss anything”) and see if the problems are resolved.
- Look at each section of treatment and see if you have met your goals:
 - Are disease processes controlled?
 - Healing adequate from the procedures you have completed?
 - Patient’s level of compliance with preventive measures adequate?

Reassessment Phase

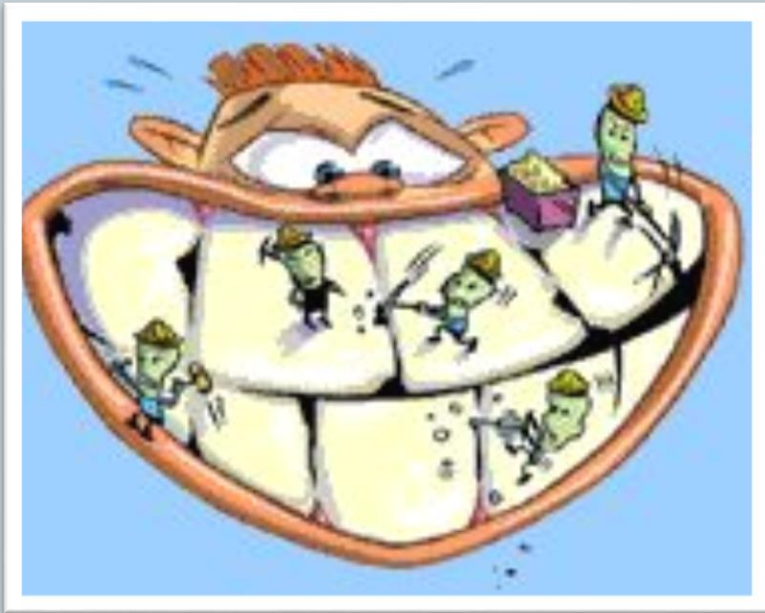

CARIES
ENDODONTICS
ORAL SURGERY
ORTHODONTICS
PERIODONTICS

Caries

Re-
eval

11



- Because caries is a relatively slow disease, it is **difficult to evaluate over the short term**. Generally, it takes 3 years caries-free to be *confident* that the disease is controlled.
- So what can we do short term to evaluate caries control?

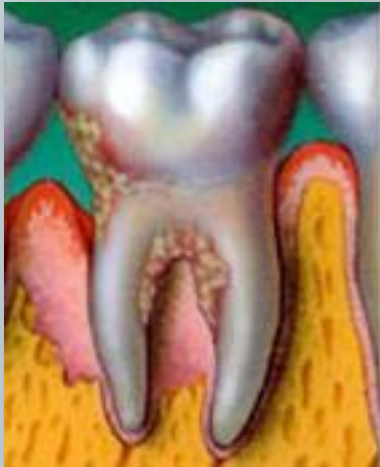Caries & Restorative Re-Eval Checklist

Re-
eval

12

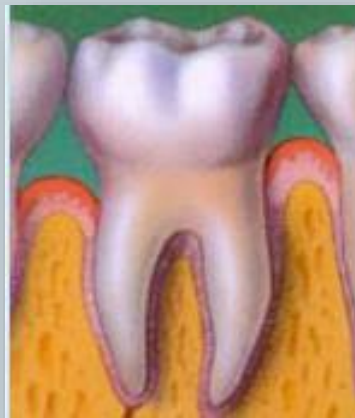- ❑ Complete all planned restorative treatment.
- ❑ Clinical exam. Do a good clinical exam with fresh eyes, with a special check on all margins, including those placed during treatment. Is it time for a D0120 (>6 mo)? Then chart it, and charge for it!!
You will in your practice....
- ❑ Caries Risk Assessment, with an emphasis on evaluating changes in patient behavior (or not!)
- ❑ Radiographs- Take new radiographs if:
 - ❑ Caries risk indicates
 - ❑ Interproximal restorations placed since last radiographs. Time to check your margins!
- ❑ Fluoride-
 - ❑ F varnish placements up to date?
 - ❑ Rx toothpaste refills needed?





This represents the patient prior to any perio therapy. There are local factors: plaque and calculus, and loss of attachment and supporting bone.

This represents a (somewhat optimistic) case after initial therapy, perio re-eval, and perio corrective surgery, which included bone grafting and guided tissue regeneration.



Overview of Phase 2

1. Remove local factors (plaque and calculus) to allow tissue to heal. OHI.
2. (*Wait 4-6 weeks*) Re-evaluate healing by probing.
3. If indicated, do surgery to access remaining calculus, reshape bone, place graft, or do guided tissue regeneration.

Periodontal Re-Eval Checklist

Re-
eval

14

- Re-chart, evaluate patient compliance over time. How is the patient responding to treatment?

This factors into the overall case prognosis as well as the prognosis of individual teeth that may be key teeth for the prosthetic treatment plan.

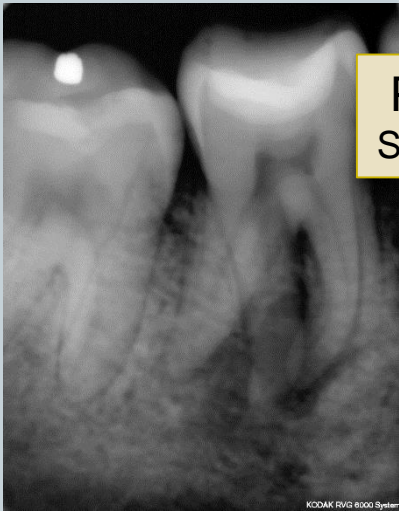

This is part of your Perio Treatment Plan, not the Operative D0003

Endodontics

Re-
eval

15

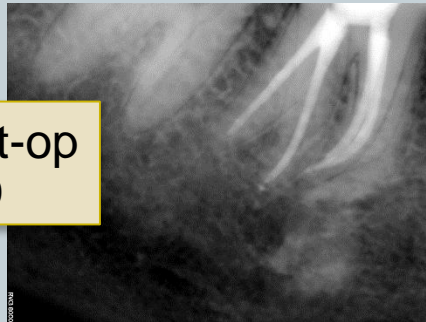


Pre-op
Sept 2009

Notice anything funny about this tooth? It's a #30, so how many roots *should* it have? How many do you see? Welcome to Endo...

1 year Post-op
Nov 2010

Notice the nice bone fill where there was a radiolucency.



- Removal of the source of the infection (non-vital pulp) can **allow the healing process** to begin.
- But it doesn't happen overnight! It takes some time (days to months) to complete the healing process, from reducing periapical inflammation to filling in bone.
- **BUT**, you don't wait for complete healing to restore the tooth!

Case courtesy Dr. Lisiane Susin



Treatment Plan Post-Endo

Re-
eval

16

- An endodontically treated tooth is one **exception** to the Phase rules:

Place a **final restoration** on an endodontically treated tooth **as soon as possible!** On posterior teeth, this usually means it must **cover the cusps, even if that treatment would normally be in Phase 3.**

- Why? Two major reasons:
 1. **Fracture.** A posterior tooth is much more likely to fracture.
 2. **Leakage.** If the provisional leaks into the endodontic filling material, it is contaminated and the endo will have to be redone.
- What if the endo *does* fail after the restoration is placed?
 - Endo can be redone through the restoration
 - The tooth can be treated surgically at the root end
 - The tooth may be deemed hopeless at that point and extracted

The point is, there is no good reason for not restoring first!



Key Concept: It's all about the **seal**

Re-
eval

17

You are fighting bacteria. Always. You have to stop them every step of their way to the apex, and every step done well increases the success rate:

STEP 1. Endo seal. The last 4-5 mm is the crucial bit and needs to be left undisturbed.

STEP 2. Chamber seal.

Anterior teeth- fill with glass ionomer or DBA

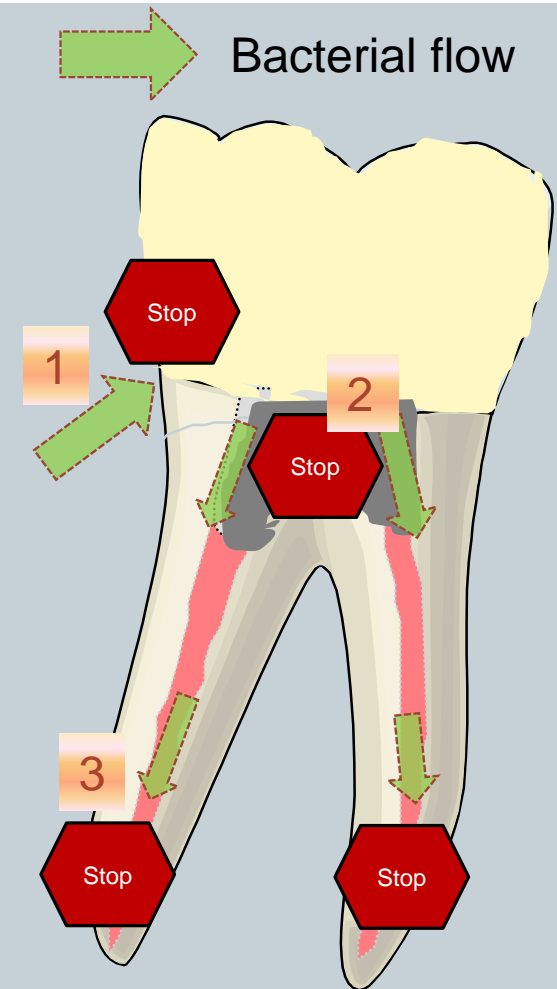
Posterior teeth amalgam with a layer of RMGI liner or composite with dentin bonding agent.

STEP 3. Restoration margins.

Anterior teeth- acid etch + composite.

Posterior teeth- full coverage (ie, crowns, onlays) cemented with our best sealing materials (ie, glass ionomer or resin cement).

Note: two of the three success points are under the control of the restorative dentist, not the endodontist!



Endodontics Re-Eval Checklist

Re-
eval

18



- ❑ History. The patient should be asymptomatic
Clinical exam:
 - ❑ Sinus tracts should be healed.
 - ❑ Percussion- should be negative
 - ❑ Palpation- should be negative
 - ❑ Probing depths- should be within normal limits (no deeper than when you started)
 - ❑ Mobility- Should be the same as adjacent or contralateral teeth.
- ❑ Radiographic exam- tricky. If there was a lesion prior to treatment, it can take **months** to fill in. Up to 5% of the time it does not fill, leaving a “bone scar.” Want to see it improving...but don’t wait to restore it!



Oral Surgery Checklist

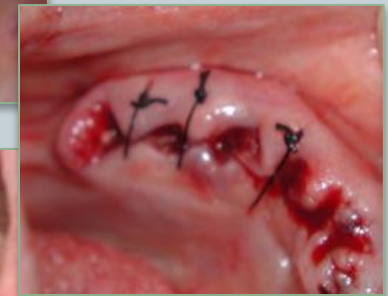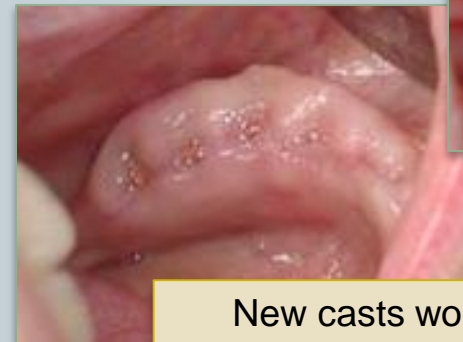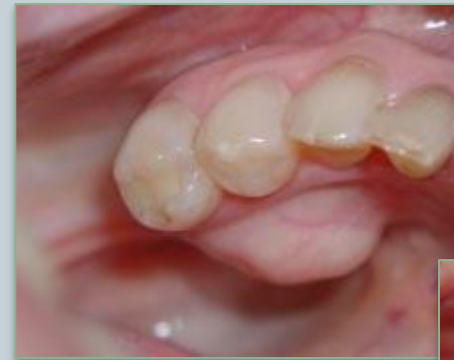Re-
eval

19

Evaluate healing by making a ***new set of impressions*** that capture extensions completely:

- ❑ Visually: Look for fistulas, drainage. Evaluate casts for adequate bone removal.
- ❑ Manually: feel underlying bone for spicules, sharp areas.
- ❑ Overall result: Did you obtain the result you needed for your prosthetic treatment plan?

Periodontally involved teeth required removal. Tori would interfere with placement of dentures and were surgically removed.



New casts would be needed that captured the area below surgical site to represent the correct denture extension



Implant Integration Checklist

Phase
2

20

1. Radiograph.

- ❑ No radiolucency around the implant. Should **not** look like a PDL on a tooth or a radiolucent halo around implant.
- ❑ Bone height should be within 1 mm of the top of the implant.

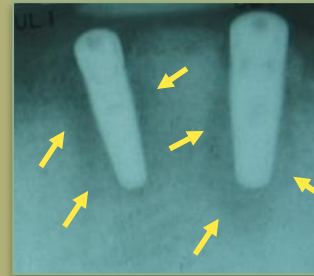
2. Clinical exam.

- ❑ Percuss (tap on the implant with a mirror handle) and listen to the sound. It should sound like tapping on marble, not a dull thud.

3. Remove the healing abutment.

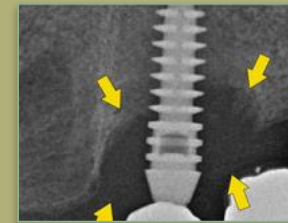
- ❑ Should be no pain
- ❑ The implant should not move

1



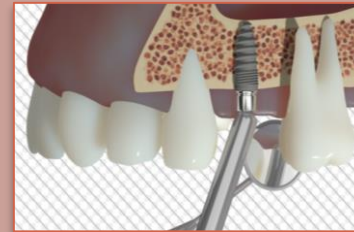
Diffuse lucency around implants

More than 1 mm height bone loss



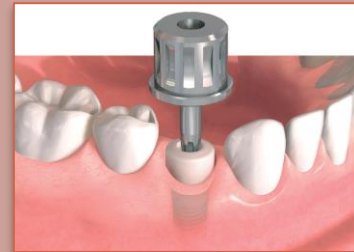Problems!

2



Percuss with mirror handle—listen for nice pinging sound

3



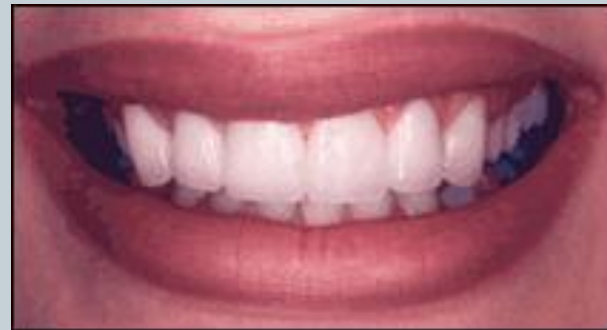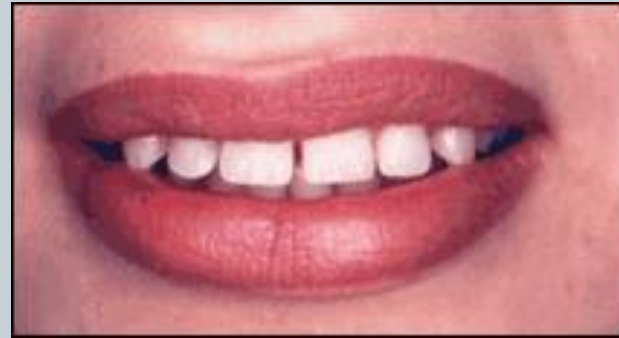Removing the healing abutment—stable and pain free.

Orthodontics Re-Eval

Re-
eval

21

- Don't assume that your orthodontist could read your mind on all the details of your planned treatment, so work with them along the way and be sure it is going the direction you want.
- Carefully evaluate the results of the orthodontics- are the teeth where you need them to be? More importantly, **are the spaces where you need them to be?**



Patient-Centered Care

Re-
eval

22



Of course you have goals and want to move forward, and your patient treatment is part of that plan. It all has to work together!

- We made a ***tentative*** Phase 3 treatment plan before we had all the information on how the patient would respond to the Disease Control Phase.
- It wasn't written in stone.
- **Remember-** *Stay flexible. This is when you need to look hard at the plan. Does it still look feasible in light of the patient's progress?*