


3. DEVELOPING A PHASE 1 TREATMENT PLAN

Treatment Planning Tutorial

Learning Objectives

1

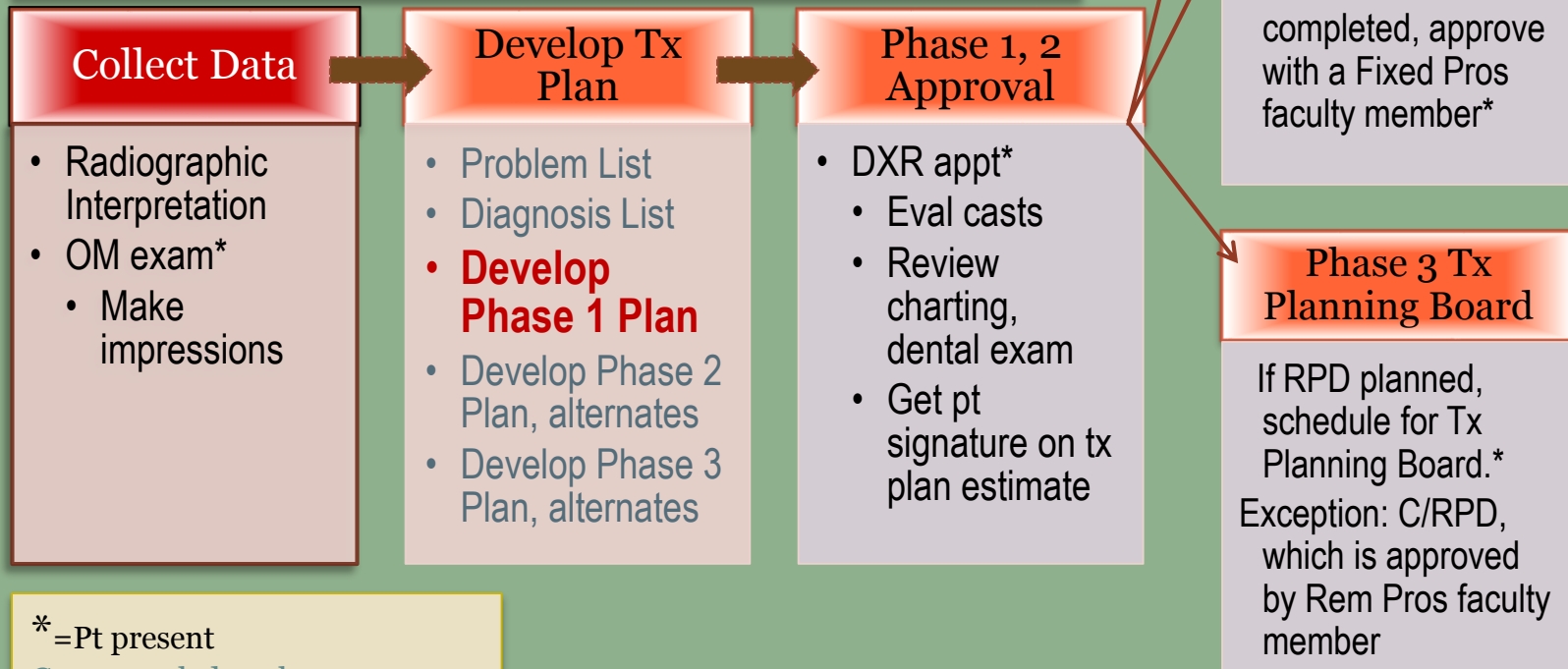
1. Explain the goals for Phase 1 and be able to recognize which treatments might be appropriate for Phase 1.
2. Be able to explain space infections, what influences their location, the sequence of treatment, and why Ludwig's Angina and Parapharyngeal space infections are a significant threat.
3. List when antibiotics are indicated and when they are not indicated.
4. List and clinically recognize the three treatment planning indications for considering an orthodontic evaluation. Recognize when a case has adequate disease control for treatment.
5. Define how to determine restorability and list the sequence of restorative and endodontic treatment.
6. List the key elements of a specialty consult. Be able to recognize and correct defects in a poorly written consult.



Additionally, all concepts in **blue** or marked with a **key** deserve special attention.

Data Collection → Tx Plan

We've developed a Problem and Diagnosis List, and have some sense for what kind of treatment this patient is interested in both tooth by tooth and overall.
Now we need to start to develop our Treatment Plan

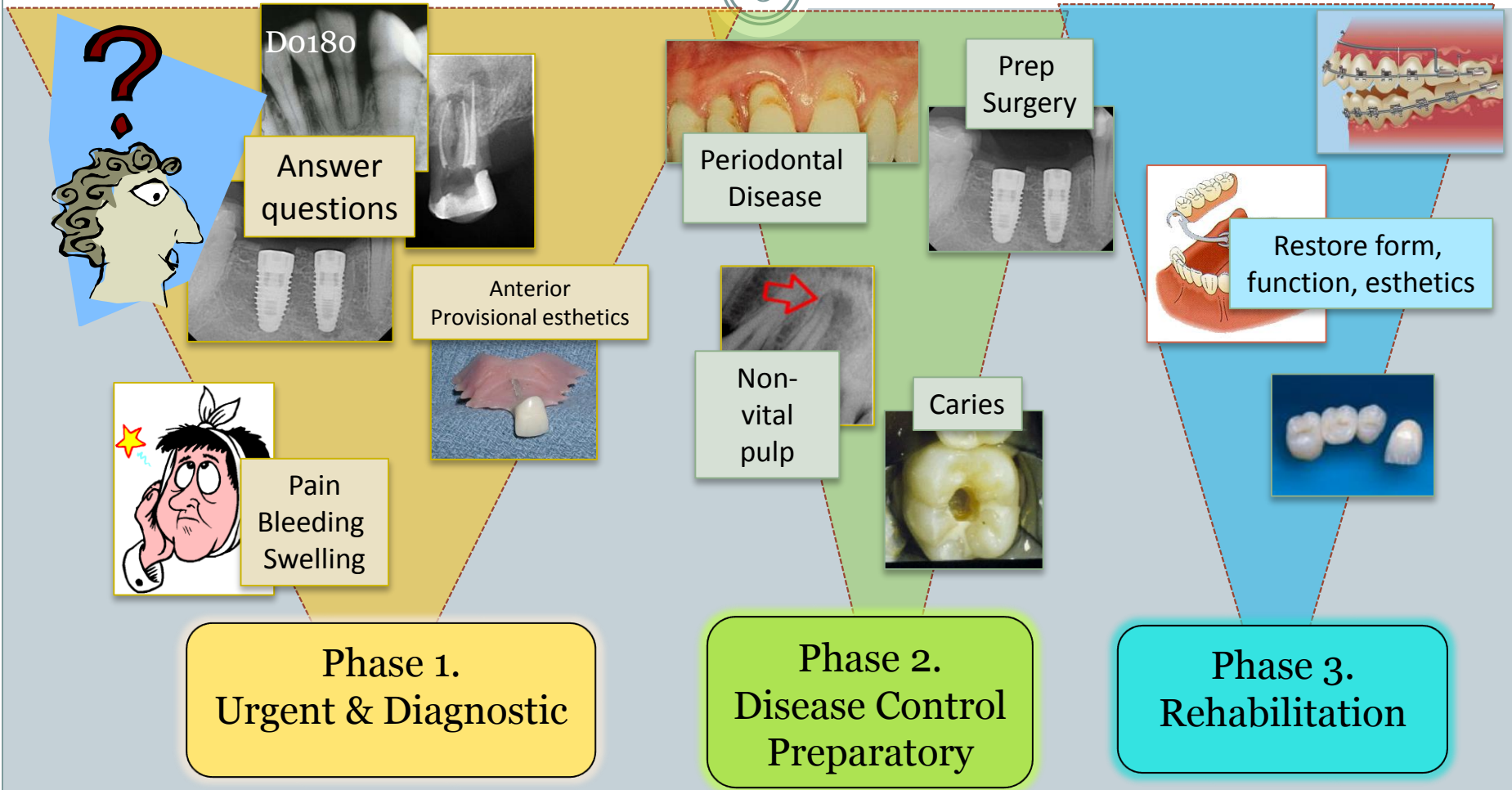


*=Pt present

Gray= work done between appts

Overview of Phases

3



Phase 1 Goals

4

- The concept behind Phase 1 is that certain treatments need to be separated out for **priority attention**.
- But intellectually, this can be a slippery slope: what should be included for first attention? Here are three broad categories of treatments:
 - **Urgent care**. Managing a patient in **pain**, with an **acute infection**, or doing a biopsy of a suspicious lesion.
 - **Esthetic “emergency”**. For some patients, losing a front tooth can be an emergency, especially if they can’t go to work without it!
 - **Answering questions**. Where there are questions that stop the treatment planning process, they go into Phase 1 so that issues are clarified prior to starting Phase 2. This includes **medical consults** and **specialty consults** like Endo, Perio, Ortho.

[Back to Review](#)

Phase 1: Urgent



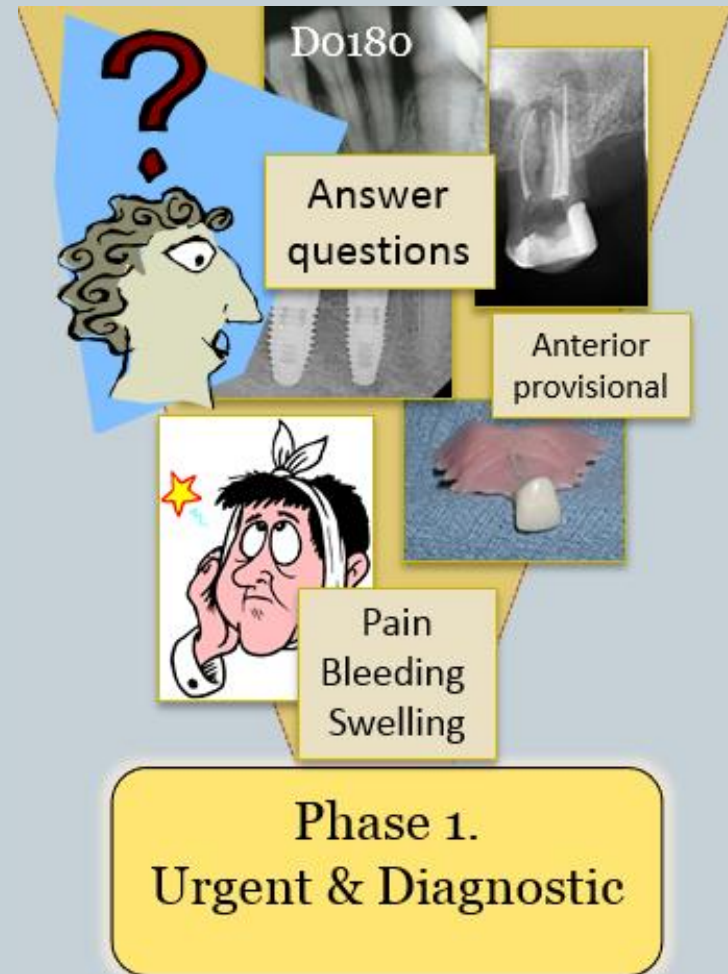
- Urgent Treatment:**
- **Space Infections**
 - **Acute Periodontal Infections**

Phase 1. Urgent

Phase 1
Urgent

5

- **Let's start with urgent.** It's easy to define: *Pain. Bleeding. Swelling. Infections.* But also *giving a patient a front tooth so they can go to work can be urgent.*
- We've covered diagnosing tooth pain already, and you will learn options for that **missing front tooth** in Prosthodontics. **Bleeding** (like from trauma) will be handled in Oral Surgery.
- What about **acute infections** and **swelling**? *Usually* swelling means an infection.



Red Flags

Phase 1
Urgent

6

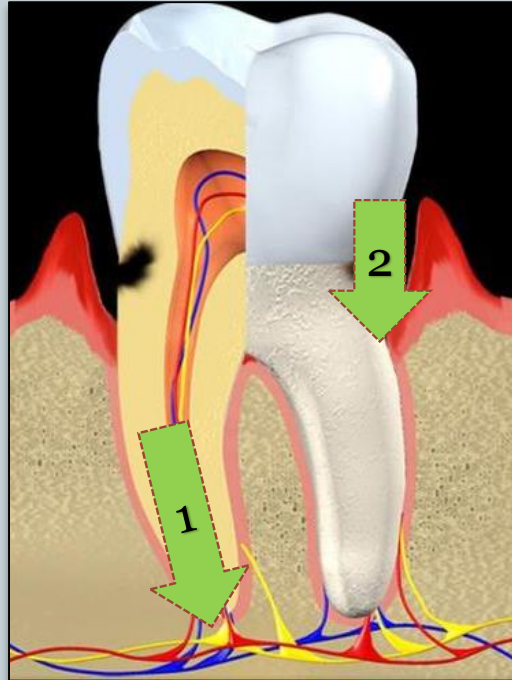
- Any of these symptoms should make you sit up and pay attention!
 - **Fever**
 - **Swelling**
 - **Trouble swallowing**
 - **Trouble breathing**
 - **Trismus**
- If you can't find the origin of the problem, or are not sure you have solved the problem, **get the patient to someone who can** (ie an Oral Surgeon)!
- **Follow these patients!** Call them even if they don't come back to the clinic.



Sources of Infection

7

1. Caries can allow bacteria to enter the pulp, which then gives access for bacteria to form a periapical abscess in the periapical bone



2. Periodontal disease causes progressively deeper pockets next to the tooth. If unable to drain, the pocket can become blocked and become an acute periodontal abscess.

From either source, the bacteria can get into deeper tissues and become a **space infection**.

Phase 1. Urgent

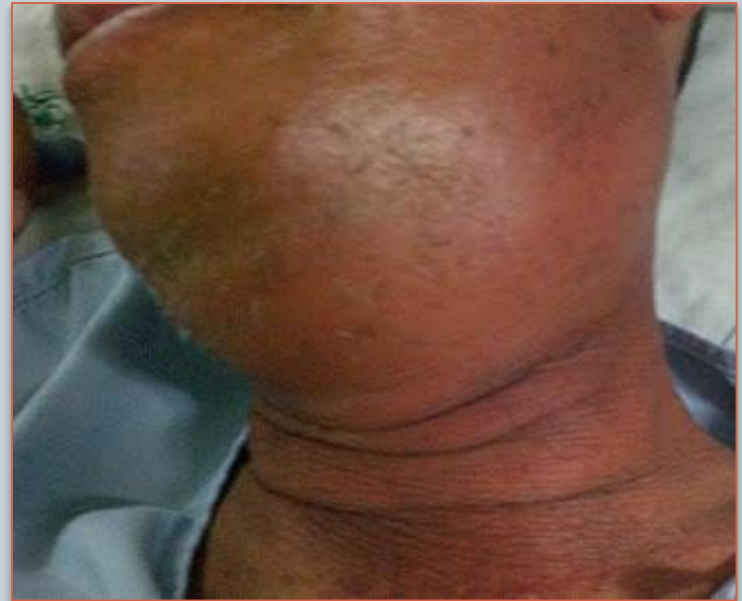Phase 1
Urgent

8

Space Infections

General concepts on management:

- Once the infection is out into the **fascial spaces**, just **starting endo or removing the tooth is *not enough***.
 1. First, the space infection must be managed
 2. Then the original problem (endo, 3rd molar, etc) is addressed.
- **“Pus must pass”** - an incision must be made into the infected area and a drain put in.
- Generally, these should be managed by an Oral and Maxillofacial Surgeon. Make friends with one—you can really learn a lot from them!



And a third major source is third molars, which you remember can cause pericoronitis.

Peterson's Steps of Management:

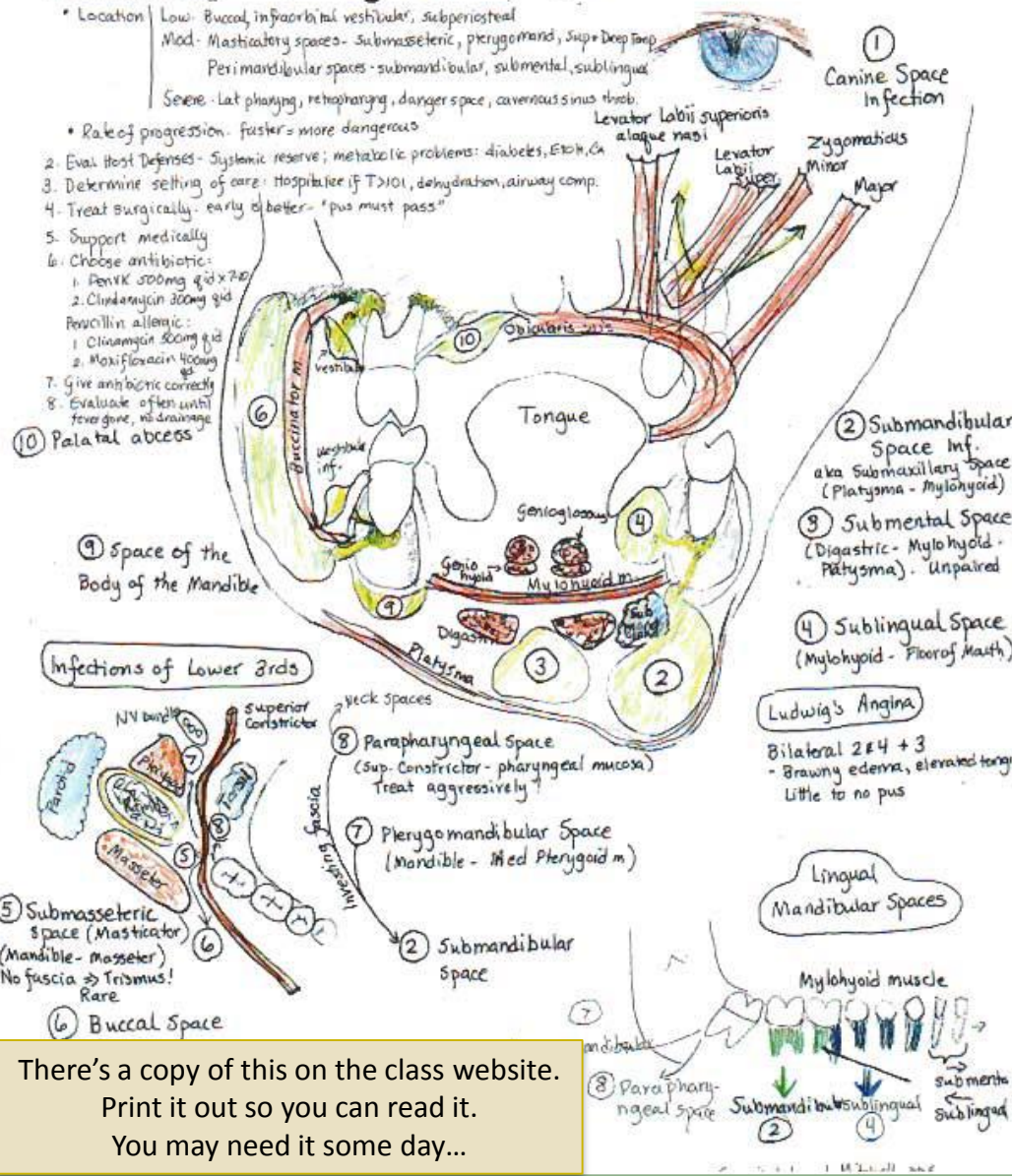
1. Determine severity

- Location
 - Low: Buccal, infraorbital vestibular, subperiosteal
 - Mod: Masticatory spaces- Submasseteric, pterygomand, Sup+Deep Temp
 - Peri-mandibular spaces- submandibular, submental, sublingual
 - Severe- Lat pharynx, retropharynx, danger space, cavernous sinus thromb

• Rate of progression - faster = more dangerous

2. Eval Host Defenses - Systemic reserve; metabolic problems: diabetes, ETOH, CA
3. Determine setting of care: Hospitalize if T>101, dehydration, airway comp.
4. Treat surgically - early is better - "pus must pass"
5. Support medically
6. Choose antibiotic:
 - 1. Pen VK 500mg qid x 7-10
 - 2. Clindamycin 300mg qid
 Penicillin allergic:
 - 1. Clindamycin 500mg qid
 - 2. Moxifloxacin 400mg
7. Give antibiotic correctly
8. Evaluate often until fever gone, no drainage
10. Palatal abscess

Space Infections



Applied Head and Neck

Let's put your Head and Neck Anatomy classes to practical use!

This is a drawing I made to help visualize and remember space infections.

Key concepts:

- Infections usually start from the apex of an abscessed tooth or pericoronitis on a 3rd molar.

- Drainage direction and structure location (like muscle origin and insertion) determine which space is infected.

-Some of the spaces are connected-infection can flow around. **Life-threatening: Ludwig's Angina** is bilateral submental, sublingual, and submandibular, pushing the tongue into the airway space.

Parapharyngeal space can go into the neck spaces which blocks off the airway.

Both of these can compromise the airway and are life-threatening.

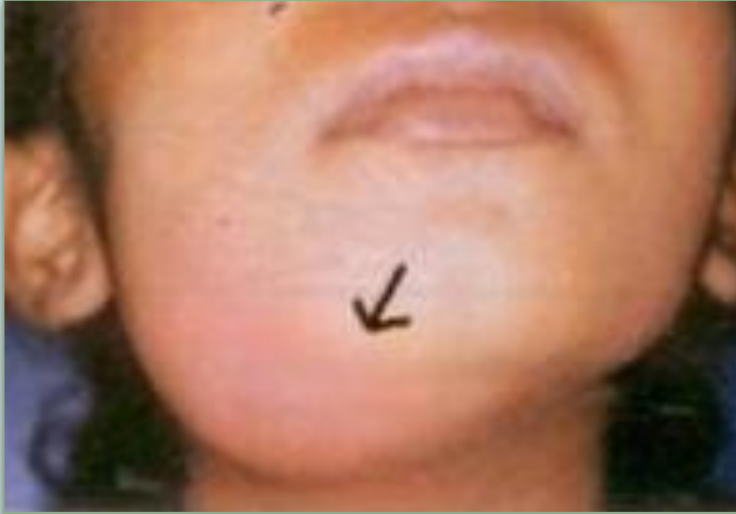- There are only 10 of these spaces, and if you think about where the muscles are and how they relate to the teeth, you can have a pretty good guess of which space is which.

Back to Review

Case 1. Suzanne

Phase 1
Urgent

9



This patient remembers having a bad toothache “a month or two ago” and then a dull ache that started about 5 days ago. Two days ago she woke up with a swelling which has rapidly worsened to this condition. The swelling is relatively hard with a soft fluctuant central area. She has a temp of 101.2.

- Which space is this most likely to be?
 - a Submandibular
 - b Submental
 - c Sublingual
- Which tooth is most likely to be the origin?
 - a #26
 - b #29
 - c #31



Indications for Antibiotics

Phase 1
Urgent

10

Not indicated:	Indicated for:
Pulpitis	Persistent infections
Necrotic pulp + radiolucency Apical periodontitis Sinus tract	Systemic illness: Temp >100, Malaise, Lymphadenopathy
Localized, fluctuant swelling (may need to be drained, but still may not need AB's)	Progressive infection: Trismus, Cellulitis, Increasing swelling
"I don't have time to take that tooth out or start a root canal today, so I'll give you this to hold you till I can get you in."	Osteomyelitis (OMFS referral!)
"I'd feel more comfortable if you took some antibiotics"	
The patient wants a prescription for <i>something</i> ...	

- While we're talking about this, let's make sure you understand when antibiotics work and **when they *don't* work.**
- Antibiotics are still hugely overprescribed for many things, dentistry among them.
- **The idea that antibiotics will help control pain in pulpitis or periapical inflammation has been disproven** in study after study but many dentists still stubbornly cling to the belief, even when confronted with the evidence.

Don't be that guy.


Back to
Review

Understanding Pain Management

Phase 1
Urgent

11

- You will take your **Pharmacology** course in the Junior year, but in the meantime, here is the basic plan for dealing with pain.
- Over the counter medications are quite effective for mild-moderate pain. We've got research. Reassure your patient—confidence works.
- Ibuprofen is dose-dependant. It is a good **pain reliever** at lower doses:
 - 400 mg every 4 hours (q4h)
 - 600 mg every 6 hours (qid)But for it to be **anti-inflammatory**, it needs to be the highest dose:
 - 800 mg every 8 hours (tid)And Ibuprofen has a **very slow onset** of relief (40 minutes). Start pts on it *before* anesthetic wears off, and have them **take it by the clock** instead of waiting until they hurt.




Mild

- Aspirin
- Tylenol
- Ibuprofen 400mg, 600 mg



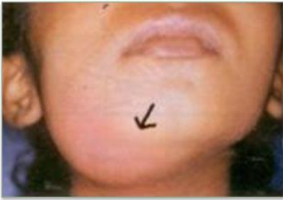Moderate

- Ibuprofen 800 mg three times a day (tid) by the clock
- Consider adding narcotics



Severe

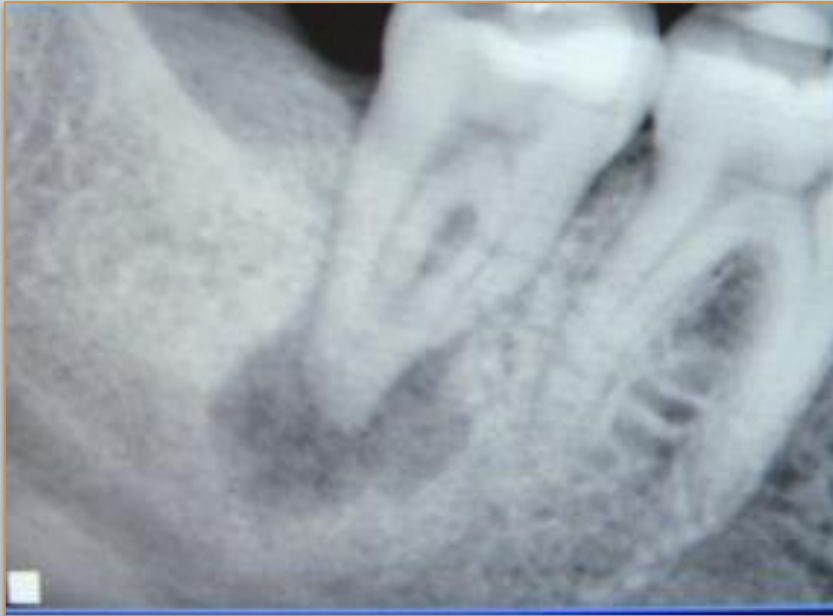- Mod + breakthrough med:
- Narcotics q4h as needed



Case 1. Suzanne

Phase 1
Urgent

12



Suzanne is an otherwise healthy patient with no allergies to any medications.

You take a radiograph and see this image. The patient wishes to save the tooth. What do you do?

- a** Start a non-surgical root canal treatment (endo) and drain through the access, start antibiotics.
- b** Incise and drain the abscess surgically, place a drain, and when the acute infection is resolved start endo.
- c** Incise and drain the abscess surgically, place a drain and start endo the same day to remove the source of the infection.

After the procedure, what will you prescribe/recommend?

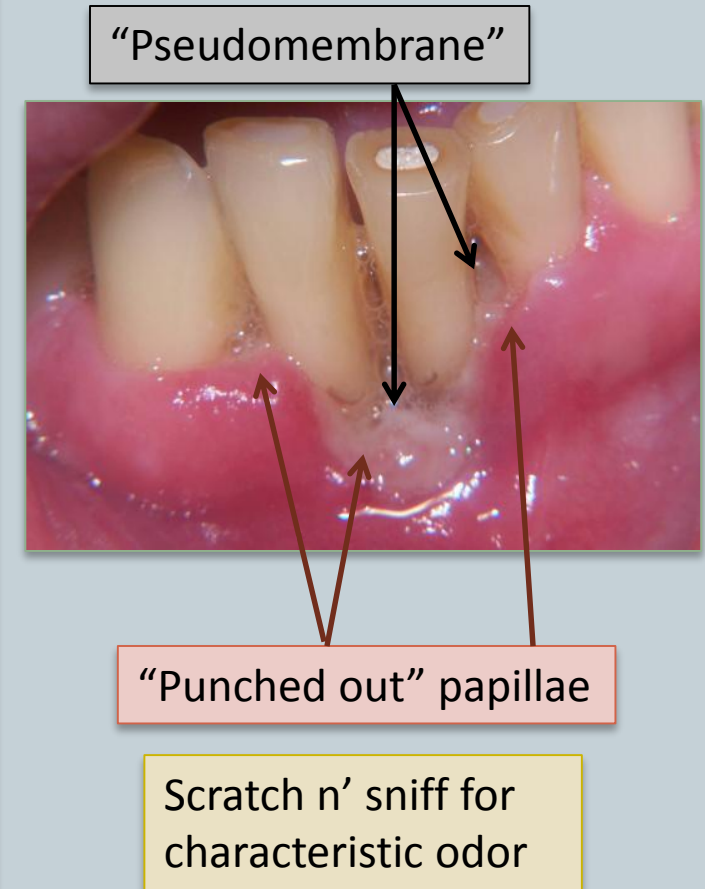
- a** Antibiotics
- b** Over the counter pain medications
- c** Narcotic pain medications

Urgent: Acute Periodontal Infections

Phase 1
Urgent

13

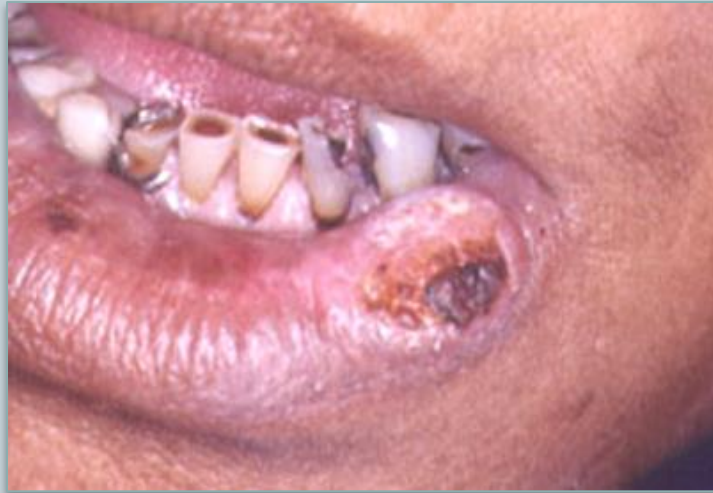- Remember learning about an **acute periodontal abscess**? Those are the kind with an obvious swollen area and can be associated with chronic periodontal disease that becomes acute, or by a specific irritant like a popcorn kernel.
- There is **another kind of periodontal disease** that is quite painful. It used to be called “**trench mouth**” because it was common in the trenches in WWI. They thought it was an infectious disease, but actually the common factor was getting shot at (stress) and eating canned food (poor nutrition).
- It was common again in the early days of HIV before current medications were available. Now you can see it on college campuses during finals (stress + cold pizza, anyone?) or boot camps or in anyone who is stressed. It’s called **Necrotizing Ulcerative Periodontitis (NUP)**.
- The bacteria invade the gingival papilla causing rapid loss of papilla, bone, and attachment mechanism. It has a classic grayish slimy “**pseudomembrane**” and “punched out” papillae and a really vile smell that you will never forget once you have gotten a whiff. **Characteristically, it tends to attack first molars and mandibular anterior molars.**
- **Treatment?** Sleep, good nutrition, and good oral hygiene as well as antibiotics.



Urgent: Biopsy Suspicious Lesions

Phase 1
Urgent

14



- Any suspicious lesions should be followed for **no more than 2 weeks**. If they have not healed significantly by then, a referral to a specialist is appropriate.
- It is your responsibility to develop a system to follow and recall these patients!
- Referrals may be appropriate to an Oral Pathologist, Oral Medicine specialist, an Oral Surgeon or a Periodontist—all are experienced in soft tissue lesions and biopsy.



England

How about a nice quiet afternoon in Chipping Campden (Chipping = market, Campa-denu= valley in Saxon) in the Cotswolds. Looks like something out of *Peter Rabbit*. Or *The Hobbit*.

This region—also known as the shires—has a rich sheep farming history that was the basis of their wealth in the medieval heyday of wool. It was grown here, sold at fairs in France and turned into cloth in Italy (especially Florence) and Flanders (Belgium).

The Prime Minister still sits on a woolsack to remember how important the wool trade is to England's prosperity.

Break Time!





These guys are Morris dancers, a traditional style of dancing that involves little bells, ribbons, and waving handkerchiefs. Traditional thatched roofs are picturesque, as are the “wool churches”, which date back to the 13th-16th C when the area was wealthy. After that, cotton began to be imported first from India, then from the South, ruining the market for more expensive wool. Whenever a region goes from wealth to relative poverty, there isn't enough money to replace the old styles with the new fashions, so this region has become a medieval time capsule.





Usually I show you food, but this is England and the food is...well, English. So imagine the smell of lavender instead!

Phase 1: Problem Solving

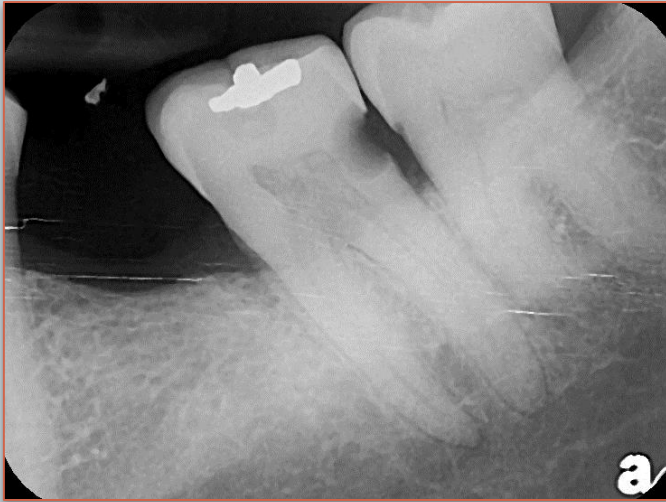


- Problem Solving:**
- **Medical**
 - **Biopsy Oral Lesions**
 - **Restorability**
 - **Periodontics**
 - **Endodontics**
 - **Implants**
 - **Orthodontics**

Phase 1. Problem Solving

Phase 1
Problem
Solving

15



Let's look at #19

Let's assume that we would really like to keep #19 for the treatment plan. So what are you thinking....

1. Does it need endo?
2. Is it restorable?

- **Problem solving** is a harder concept, and we need to spend some time on this one.
- Let's look at the kinds of questions we might be asking:
 - Is that soft tissue lesion anything we should worry about?
 - Is this tooth restorable?
 - Does the endo need to be redone before I put a crown on it?
 - Can I plan implants for that space? How many will I need?
 - Should we do ortho first?

Answer Medical Questions

Phase 1
Problem
Solving

16

- As you were taught in Oral Medicine, **you** are the best-trained person to know the parameters for dental care.
- But if there are issues in the medical history that require clarification or testing, the time to get the answers you need is before you start treatment.




Is this tooth restorable?

Phase 1
Problem
Solving

17

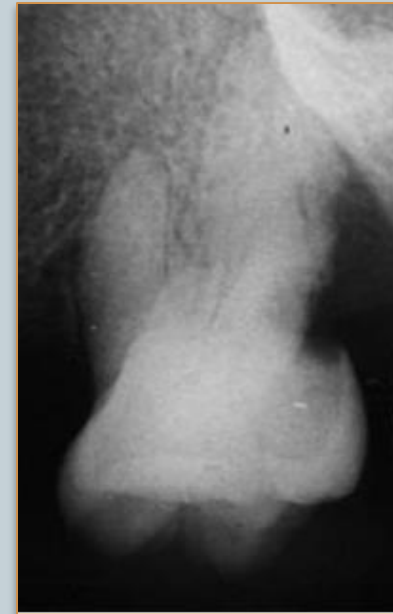
- Let's get to the **bottom line**: You generally can't tell from a radiograph or even clinically if a tooth is restorable or not if it's borderline.
- **What works?** Remove the caries and see if you can get a **matrix band** on it. If you can get a matrix band on it, then you can restore it.

 **Crucial concept:** you must determine if the tooth is restorable *before* you do endo. Why?

1. Sequencing correctly keeps you from the **embarrassment** (!) of extracting a tooth you just did a root canal on.

Let's say you don't plan, and after the endo you find out the tooth is NOT restorable! Ouch! (Pull out your checkbook...)

2. A good restoration helps to hold on the **rubber dam retainer**.
3. With a good restoration in place, you can better **control the sodium hypochlorite (bleach) irrigant** used in the root canal procedure—it won't leak out through the deep cavity if there's a nice restoration in it.



Sure Endo can do a root canal on this tooth.

But then can it be restored?

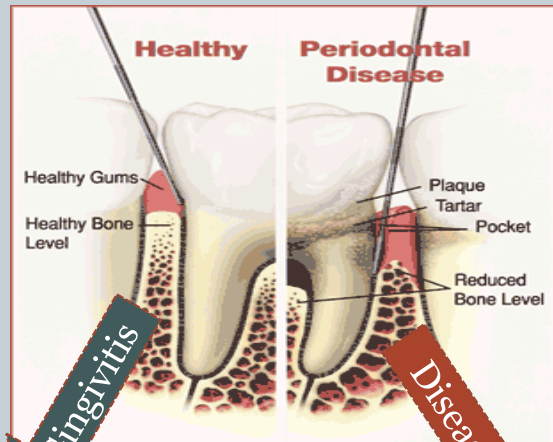
Don't assume so... need to find out **first by excavating caries and attempting to restore!**

Not only do you *know*, but then isolation is better and easier for Endo, and the irrigant won't leak out.

Periodontics

Phase 1
Problem
Solving

18



Gingivitis

Disease

Supragingival
calculus and/or
Stain and/or
Pocket depth
<4mm

Prophylaxis
D1110



1. Subgingival Calculus + Bleeding on probing **and/or**
2. Pocket depth > 4mm in several areas + Radiographic bone loss **or**
3. MG defects

Comprehensive
Periodontal Evaluation
D0180

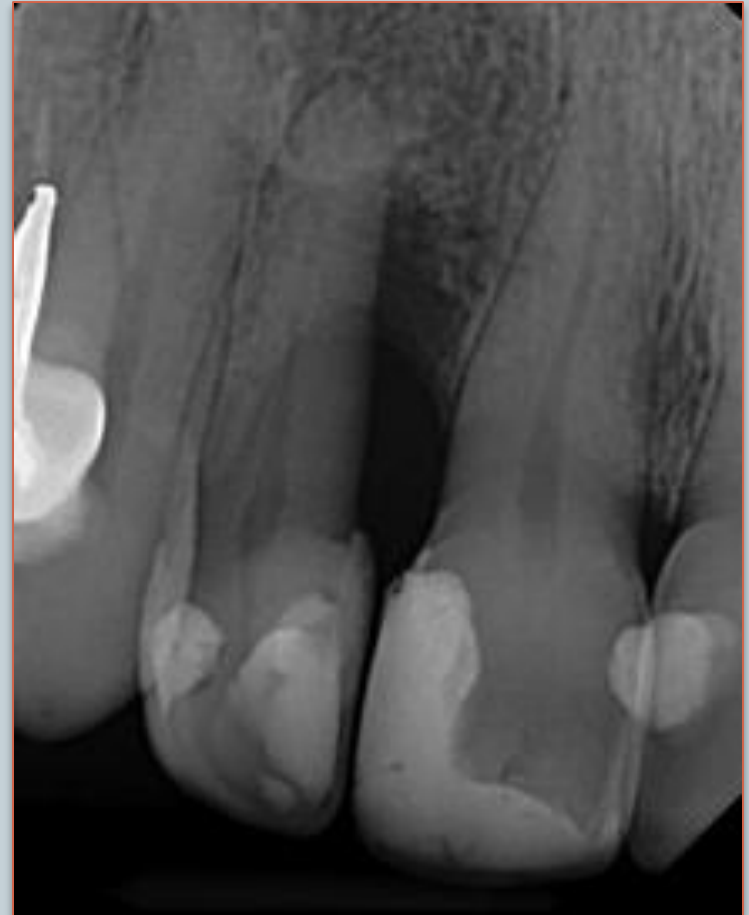- If you find that your patient meets the criteria (*memorize them now...*) for disease on your initial exam:
- Schedule the patient for a **periodontal consult**, which is called a **Comprehensive Periodontal Evaluation (D0180)**.
- This, like all consults, is usually a Phase 1 procedure.

Periodontics

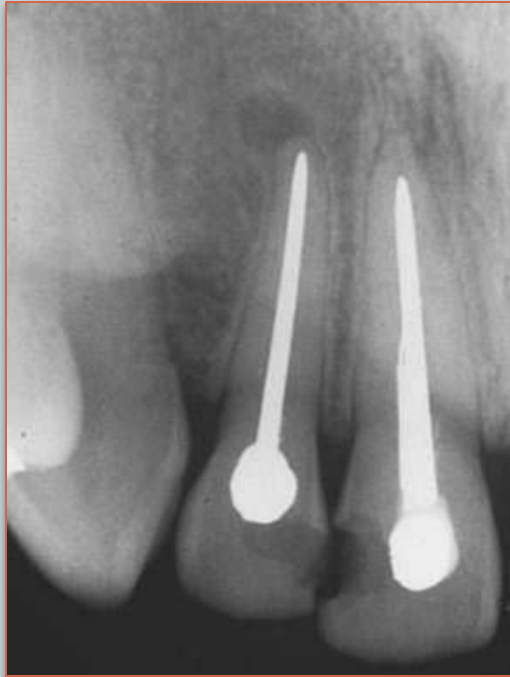Phase 1
Problem
Solving

19

- **The question-** Is tooth #7 savable periodontally? If so, what would be required?
- This patient would require a **D0180** rather than just a prophyl, right?
- Your perio exam will look at each tooth on its own, but also keep in mind your overall treatment plan, and what role this tooth might play.
- Are you thinking of using that tooth to support an FPD? An RPD? You might run that past the periodontist as part of the overall consideration.



Endodontics



What if you are thinking of putting crowns on these teeth for esthetics? Would you need to redo these endo txs first? It be smart to do that... I'd sure **ask an endodontist.**

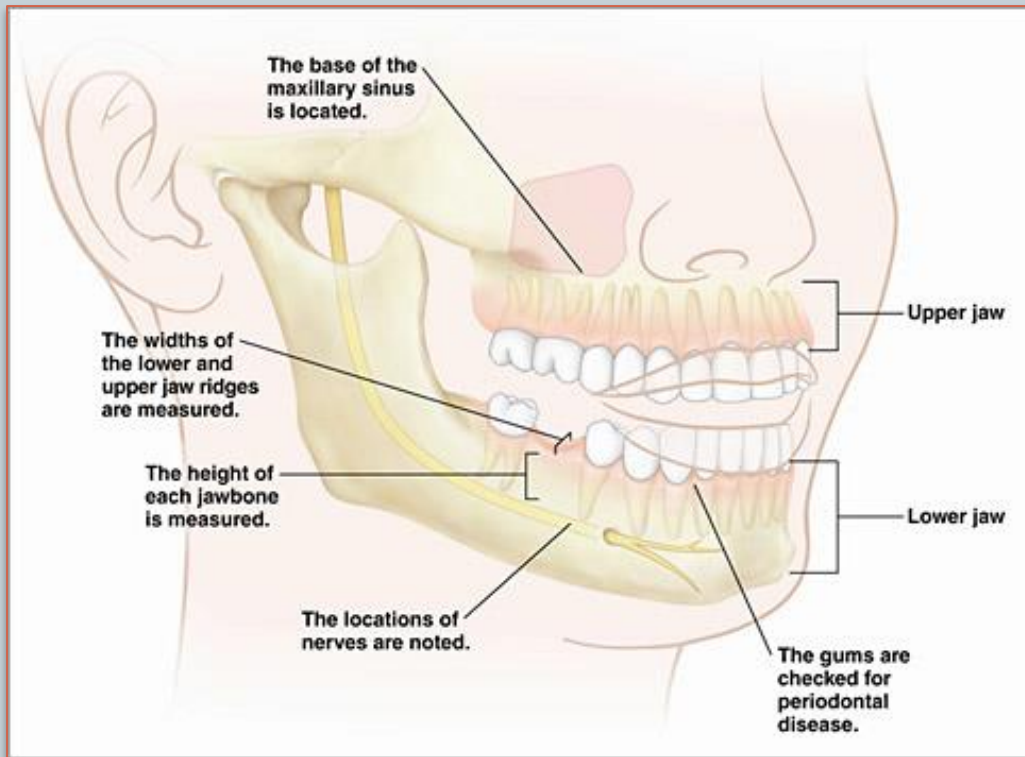
What sorts of situations call for an endo referral?

- If the tooth is already endo treated *but*:
 - Is still **symptomatic**.
 - Has **not been restored correctly** and the endo fill itself (the gutta percha) has been exposed to saliva for more than 3-4 weeks. The oral bacteria have contaminated the endo fill and it should be evaluated for re-treatment.
 - The previous fill seems to have significant problems **and** you plan significant restorative treatment on it (ie, use as an RPD abutment) .
- Any issues of pathosis in the chamber or periapical region, such as resorption or progressing calcification.

Implants

Phase 1
Problem
Solving

21

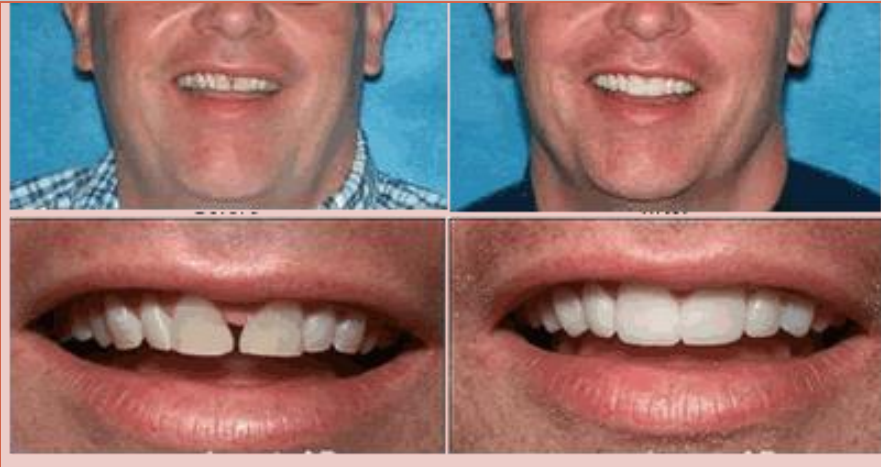

- We will talk more about implants in a later tutorial, but for now let's say the patient is interested. Are implants a *feasible* option?
- The **major questions** are:
 - Is there enough bone to support an implant?
 - Is there enough space for the crown /FPD?
 - Is the patient a good candidate health-wise and psychologically?
- You will go through patient services, who will assign them to one of three departments for an evaluation. (Oral Surgery, Perio, GPR)

Specialty Consults: Orthodontics

Phase 1
Problem
Solving

22



This patient had a single large space between his centrals partly closed with composite. Imagine how BIG these teeth would be if veneers were placed on them in this position! But after ortho, the space was shared and the teeth could be sized normally for a nice result.

- Ortho- it's not just for kids any more!
- It can be quite helpful in setting up **restorative care**.
- You will learn more in your ortho class, but for now, consider ortho when dealing with:
 1. **Space or crowding** issues if you're doing Fixed Pros
 2. **Implants!** Once they are in, you can't move them, or the teeth around them. **Think of ortho before you put in implants!**

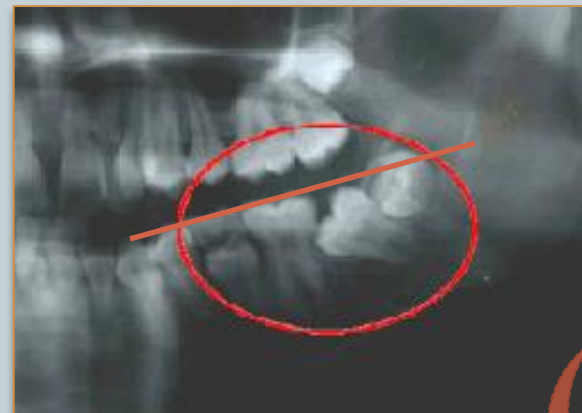Orthodontic Adjunctive Care: Molar Uprighting

Phase 1
Problem
Solving

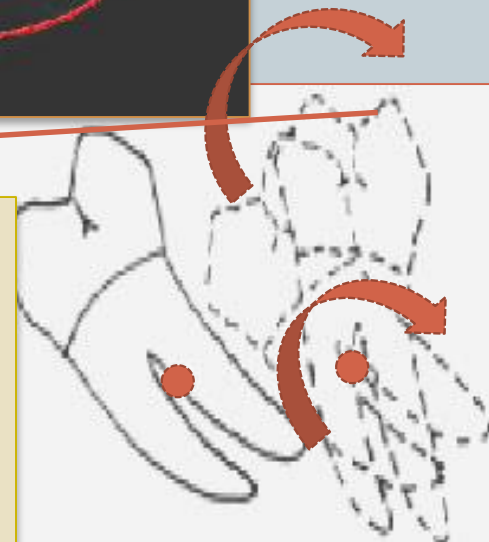23

3. Tipped molar. Sometimes you want to use for an FPD abutment, but you can't prepare it correctly if it's tipped too far—you'll see why in Fixed Pros lab.

- ❖ But notice the **center of rotation**—a point in the center of the root.
- ❖ This usually means the crown rotates **above the plane of occlusion**—keep that in mind for your planning.
- ❖ Finally, ortho is NOT a fairy-dust answer: you can't just say "Oh, I'll have ortho move those teeth," without knowing that it is *feasible*. You have to move teeth where there is bone, for example. It's harder than it looks....



In this case, the tooth is well below the plane of occlusion, so after uprighting it will probably only need minor adjustment. But if it was at or above the plane, it would end up well above it and maybe unusable.



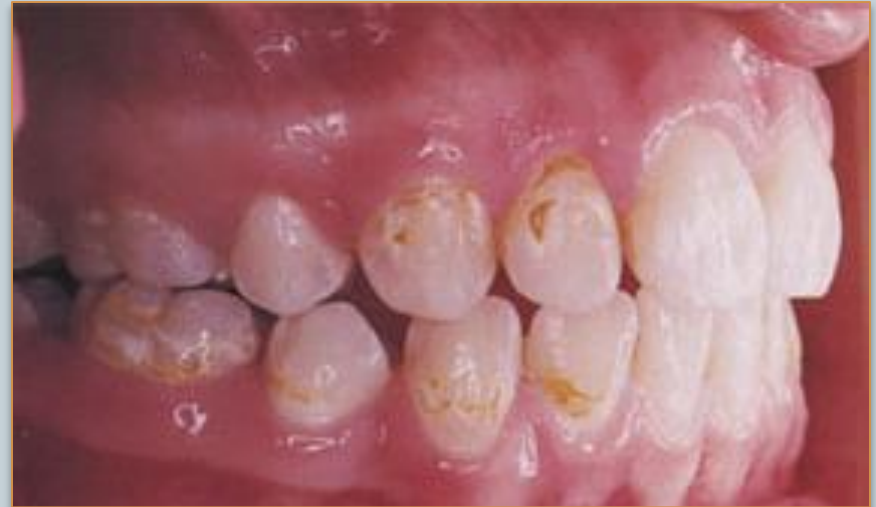Adjunctive Orthodontic Care

Phase 1
Problem
Solving

24

BUT

- While the orthodontist will answer your referral, **before they actually start the case** (usually later in phase 2 or phase 3), they will need to know about the patient's disease status:
 - Is the patient **caries active**?
 - Does the patient have **active perio disease**?
- Why? Because **Ortho treatment will aggravate both of these diseases** and the patient will be *worse off* than if they had not had the treatment.
- You want to have a good working relationship with your referring orthodontists **to get these diseases under control before placing appliances**.
- **More about that in Phase 2 and the Re-Evaluation tutorial.**



Note the pattern of caries and white spot lesions around areas where the brackets were bonded, where the *S. Mutans*-laden plaque builds up. This is not the esthetic result orthodontists want to show on their websites! It's much harder to brush and floss around ortho appliances, too, so perio disease is a consideration.

Back to
Review

Writing a Specialty Consult




**INTRODUCE YOUR PATIENT
PERTINENT MEDICAL HISTORY
KEY CLINICAL FINDINGS
EXPLAIN CONTEXT
“THE ASK”**

Introduce your patient

25


- Basic demographic data
“This 46 yo AA female...”
- Patient’s original presenting concerns
“...presented for pain in #5 area...”
- History of present illness, if pertinent
“...which was treated with non-surgical root canal treatment in 1996.”



No one knows your patient and their problems as well as you do. When you hand off care to another provider, make it as smooth, seamless, and professional as possible.
*That means **good information transfer.***

Pertinent Medical History

26



- List medical items of concern to the specialist with a brief synopsis of level of control

“Pt is ASA Class II with Type II diabetes well controlled with diet and Metformin. HbA1C on (date) was 7.1.”
- Social/anxiety issues.

“Pt is very anxious and wishes to discuss sedation for any surgical procedures.”

Key Clinical Findings

27

- Organize and lay out the key clinical findings of concern.
“Clinical exam of upper right shows normal soft tissue. Percussion, palpation all within normal limits except #5, which is sensitive to both. All perio probings similar to contralateral. Radiograph shows periapical radiolucency #5 (copy attached). Existing RCT is a silver point fill. No other radiographs available for comparison.”



Explain Context

28



- Give a brief synopsis of your thinking or plans.

“This tooth is being considered as an abutment for either an FPD or RPD; however, if the prognosis is poor, the patient is open to extraction and placement of an implant.”

The Ask...

29

- Clearly state what you want from this patient encounter, either an opinion or a treatment.

“Please evaluate for whether the long-term prognosis of this tooth as an abutment would justify retreatment with endo, post and core, and full coverage. If so, please proceed with treatment.”



Consults (Referral) in axiUm

30

The screenshot shows the axiUm software interface. At the top, there is a dental chart with teeth numbered 1 through 16. Below the chart, there are tabs for 'In Progress', 'Tx History', 'Tx Plans', 'Forms', 'Attachments', 'Perio', 'Labs', 'Medications', and 'Chart Add'. The 'Forms' tab is selected. A 'Medical Alerts' panel is visible on the right, showing 'Allergies/Hives' and 'Current Medications'. The 'Add Form' dialog box is open, showing a list of form types. The 'Form' dropdown is set to 'REFER'. The 'OK' button is highlighted. Red circles and numbers 1-5 indicate the steps: 1. Clicking the 'Forms' menu, 2. Clicking the green plus icon, 3. Clicking the 'Form' dropdown, 4. Clicking 'REFER', and 5. Clicking 'OK'.

- Hang on. This is hard...
1. Go to Forms.
 2. Click the folder with the green plus on the right.
 3. Click on the Form options
 4. Choose REFER
 5. Click OK.

Referral: Choosing the “To”

31

The screenshot displays a dental EPR interface. At the top, there is a dental chart with teeth numbered 1 through 16. Below the chart, there are tabs for 'Alerts', 'Problems', and 'Objectives'. A 'Medical Alerts' section lists 'Allergies/Hives' and 'Current Medications' including 'Diovan every day- HTN'. A pop-up window titled 'EPR Question Details - Additional Info' is open, showing a dropdown menu for 'TO ORTHO'. Below this, there is a list of clinic options with checkboxes. The 'TO ORTHO' option is checked and highlighted with a blue background. Other options include 'TO DENTAL ASSOC (DPG)', 'TO DENTAL HYGIENE', 'TO ENDO', 'TO GPR', 'TO ORAL MED', 'TO OMS', 'TO PATHOLOGY', 'TO PATIENT SERVICES - JR CLINIC', 'TO PATIENT SERVICES - SR CLINIC', 'TO PEDIATRIC CLINIC', 'TO PERIO', 'TO PROS', 'TO RADIOLOGY', and 'TO EXTERNAL CLINIC'. The main form below the dropdown is titled 'REFERRAL REQUEST' and has fields for 'To (Clinic)', 'From (Clinic- Provider)', 'FROM DENTAL ASSOC (DPG)', 'From Provider Name', and 'REASON FOR REQUEST (Complaints and Findings)'. The 'To (Clinic)' field is circled in red. The 'From Provider Name' is 'J. Mitchell'. The 'REASON FOR REQUEST' field contains text: 'This 52 yo AA GRU hospital employee following a traumatic injury on the job. injuries were attended to, other routine been prioritized, including caries. Med includes well controlled HTN. #11 is significantly carious and non-vital restoration included.'

Click on “To (Clinic)” and a list of clinics appears. Click on the box for the place where you want the referral to go.

Referral: Choosing the “From”

32

Medical Alerts:
Allergies/Hives

Current Medications:
Diovan every day- HTN

EPR Question Details - Additional Info

FROM JR CLINIC

From Provider Name

Provider #

Attending Provider Name (first/last)

In Progress Tx History Tx Plans Forms Attachments Perio Labs

Change Date 06/23/2014 NEW

Referral Request

Form Question	Answer
REFERRAL REQUEST	
<input checked="" type="checkbox"/> To (Clinic)	
<input type="checkbox"/> TO ORTHO	Y
<input checked="" type="checkbox"/> From (Clinic- Provider)	
<input type="checkbox"/> FROM DENTAL ASSOC (DPA)	Y
From Provider Name	J. Mitchell
REASON FOR REQUEST (Complaints and Findings):	This 52 yo AA GRU hospital employee following a traumatic injury on the job. injuries were attended to, other routine been prioritized, including caries. Med includes well controlled HTN.

- FROM JR CLINIC
- FROM ORAL MED
- FROM ORTHO
- FROM OMS
- FROM PATHOLOGY
- FROM PEDIATRIC CLINIC
- FROM PERIO
- FROM PROS
- FROM RADIOLOGY
- FROM SCREENING
- FROM SOPHOMORE BLOCK
- FROM SR CLINIC
- FROM EXTERNAL CLINIC OR SOURCE

Click on “From (Clinic-Provider)” and a list of clinics appears. Click on FROM JR CLINIC. It isn’t necessary to add the faculty name since they sign the referral, unless someone else was the key instigator.

“Reason for Request” Go-By

33

Now fill in the “REASON FOR REQUEST”

- **This XX yo (race) (male/female) presents for (original concern). Medical history includes** (concise evaluation of issues of significance to procedure considered).
- **Clinical findings include** (whatever led you to ask for a consult, ie, for Endo, a poor fill with radiolucency, percussion and palpation sensitivity; for OS, a non-restorable carious tooth or that tooth will be removed for restorative reasons; for Ortho, crowded lower anterior teeth; for Perio, a description of area/condition of concern). Advise of any special concerns or issues, esp. if sedation is a consideration.
- **Current treatment options being considered include** (explain your plans so the specialist understands the context for this treatment. Ex: placement of implants, restorative plan).
- **Please evaluate and treat...; evaluate and advise if ...** (If you do not want treatment performed at this time, say so....)

[Back to Review](#)

Now that you know the basics...



- **Read Chapter 3 pg 53-65** (before occlusion): Developing the Treatment Plan
- **Skim Chapter 6 pg 113-135**: Acute Phase of Treatment. Gives you a very good overview of how to handle an emergency patient start to finish. Also has a good review of the pain material we covered last semester, but in more detail.

Review of Learning Objectives



If you have trouble with any of these, click on the link. Some cover several pages before the Return to Review button appears. Be sure you know all the terms in [blue](#) in the tutorial.

1

Explain the goals for Phase 1 and be able to recognize which treatments might be appropriate for Phase 1.

2

Be able to explain space infections, what influences their location, the sequence of treatment, and why Ludwig's Angina and Parapharyngeal space infections are a significant threat.

3

List when antibiotics are indicated and when they are not indicated.

4

List and clinically recognize the three treatment planning indications for considering an orthodontic evaluation. Recognize when a case is disease controlled for referral

5

Define how to determine restorability and list the sequence of restorative and endodontic treatment.

6

List the key elements of a specialty consult. Be able to correctly write a referral in axiUm. Recognize and correct defects in a poorly written referral.

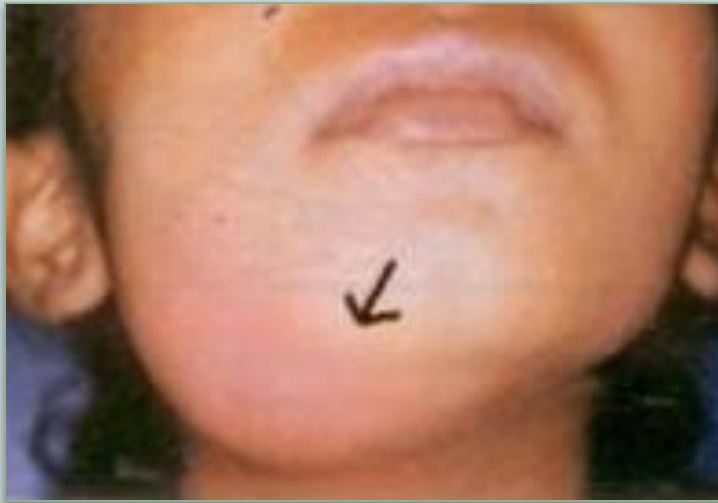Nice work!

St James Church
Chipping Campden

JK Mitchell, DDS

Finish

Case 1: You chose a “Submandibular Space”



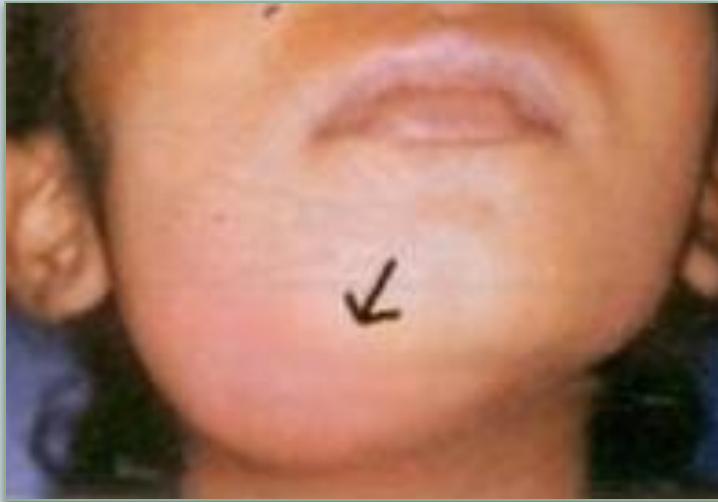Correct!



- You probably noticed that the swelling is on one side only (eliminating the unpaired Submental space which would be right in the middle) and that it is under the Mylohyoid muscle.
- Nice work!

Return

Case 1: You chose b “Submental Space”



- Probably not.
- Check the diagram and try again!

Return

Case 1: You chose c “Sublingual space”



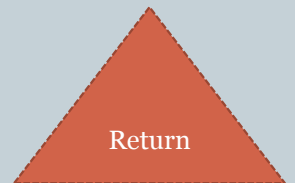
- Probably not
- Check the diagram and try again!

Return

Case 1: You chose a “#26”



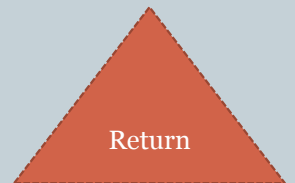
- Probably not...
- Check the diagram and try again!

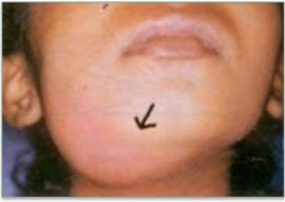

Case 1: You chose b “#29”



- Probably not.
- Check the diagram and try again!

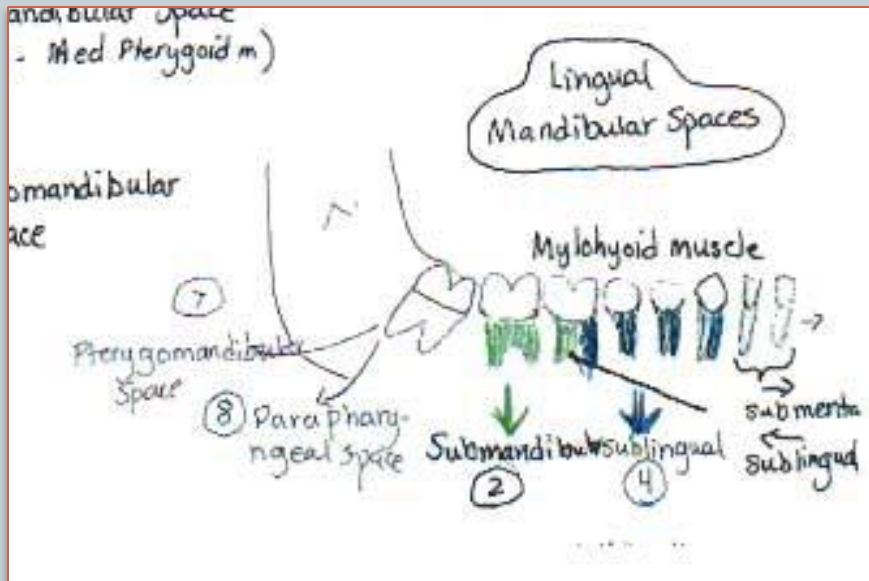




Case 1: You chose c “#31”



Correct!

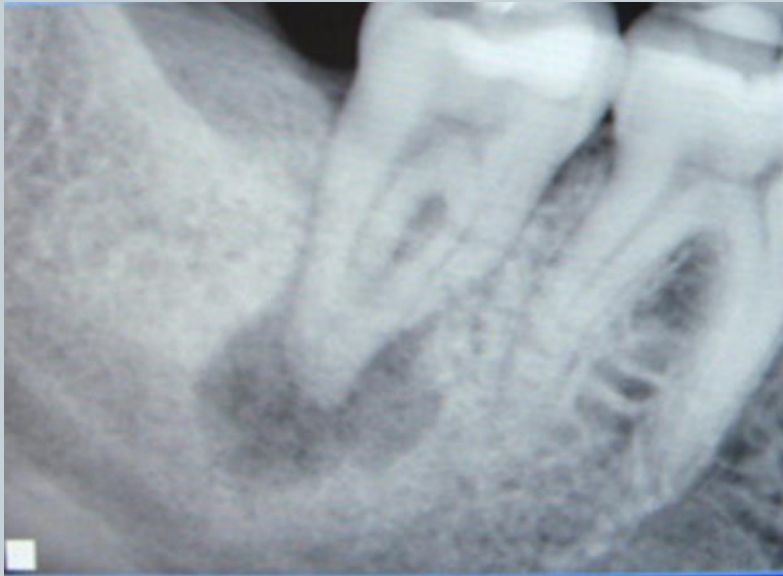

- You probably noted that the most likely tooth to be below the mylohyoid insertion is a second molar, so #31 is a likely option.
- Nice work!

Return



Case 1. You chose a- Endo



- Not really the best choice.
- Read the slide on infections and try again!

Return

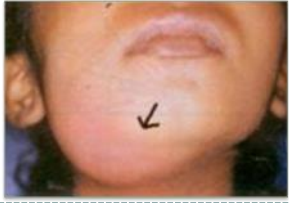You chose b.



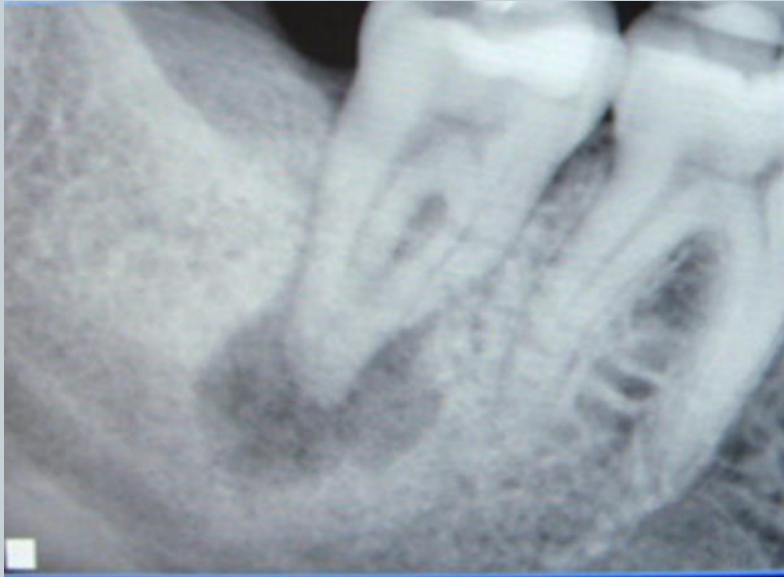I&D, delay endo - Correct!

- Of course you want to get the endo done as soon as you can, but generally patients like this will have trouble opening their mouths wide enough to work on and you will make them much more sore if you try to do it all at once.
- Good job!

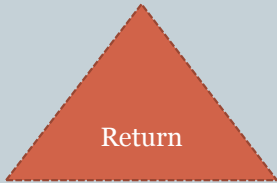
Return

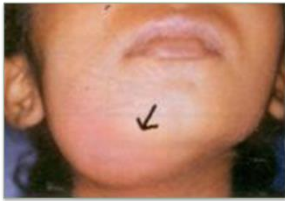

Case 1. You chose c- I&D + Endo



- Not really the best choice.
- Read the slide on infections and try again!





Suzanne: You chose Antibiotics

Not indicated:	Indicated for:
Pulpitis	Persistent infections
Necrotic pulp + radiolucency Apical periodontitis Sinus tract	Systemic illness: Temp >100, Malaise, Lymphadenopathy
Localized, fluctuant swelling (may need to be drained, but still may not need AB's)	Progressive infection: Trismus, Cellulitis, Increasing swelling
"I don't have time to take that tooth out or start a root canal today, so I'll give you this to hold you till I can get you in."	Osteomyelitis (OMFS referral!)
"I'd feel more comfortable if you took some antibiotics"	
The patient wants a prescription for <i>something</i> ...	

YES!



- This is clearly a case for antibiotics. The patient has a fever and a progressing infection.
- Good choice, doctor!
- Keep clicking, though

Return



Suzanne: You chose OTC Pain Meds



Good idea!

- Not because that is going to be enough for her pain after the I&D surgery (it won't be) but because it is anti-inflammatory. You would give it at the highest dose:
 - 800 mg every 8 hours (tid)
- She will have less overall pain if the inflammation is controlled, not just the pain.
- Keep looking, though

Return



Suzanne: You chose Narcotic Pain Meds



Of course.

- This woman is going to be in a lot of pain after we open up her neck, drain out a lot of pus, and put in a drain. This is *not* a fun day. Ibuprofen is *not* going to keep her comfortable.
- Patients need narcotics for this sort of pain, and you are wise to prescribe it in advance of the pain.
- Keep looking, though

Return