

GRANULOMATOSIS WITH POLYANGIITIS (WEGENER'S) – CASE REPORT – STIL KOUNTAKIS, MD, PHD

The patient is a 58 year-old female who was diagnosed with granulomatosis with polyangiitis in 2017 after a workup for pulmonary nodules. She had sinusitis symptoms and sinus disease on CT and underwent septoplasty with endoscopic sinus surgery in 2018 at an outside institution. The patient presented to our clinic with nasal obstruction, crusting and olfactory dysfunction. She was being treated with methotrexate and prednisone by her rheumatologist. She also had been treated with normal saline irrigations BID, and BID nasal irrigations with budesonide and clindamycin by her otolaryngologist.

Nasal endoscopy revealed severe crusting and a large septal perforation. The patient had saddle nose deformity. Endoscopic debridement in the office improved her nasal breathing and showed extensive mucosal inflammation and scarring.

A sinus CT was obtained (Figure 1) that showed a large septal perforation, mucosal thickening within the maxillary sinuses bilaterally, hypoplastic completely opacified frontal sinuses, mucosal thickening of the ethmoid labyrinth and sphenoidal sinuses bilaterally. No fluid levels were identified. There was extensive defect of the nasal septum, as well as bony erosion/dehiscence of the anterior lamina papyracea bilaterally, and diffuse bony thickening of the greater sphenoidal wing, and maxilla.

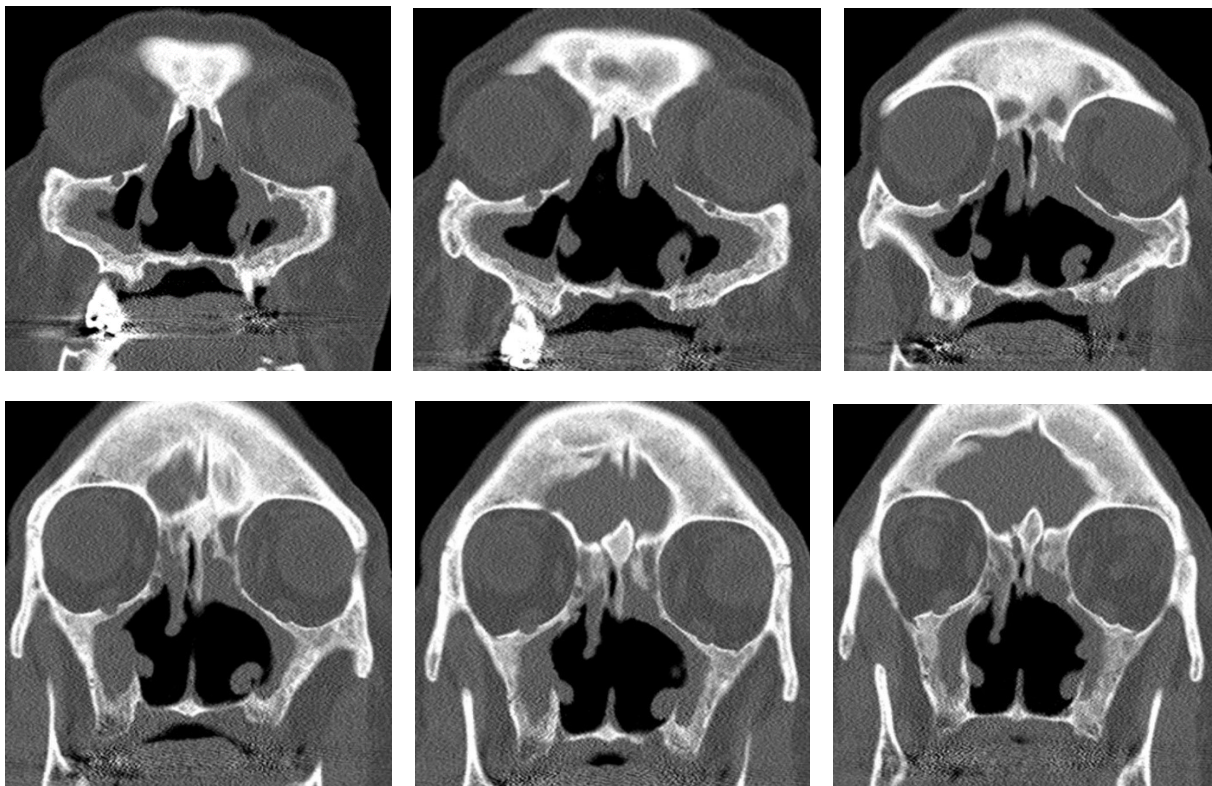


Figure 1: Coronal Sinus CT

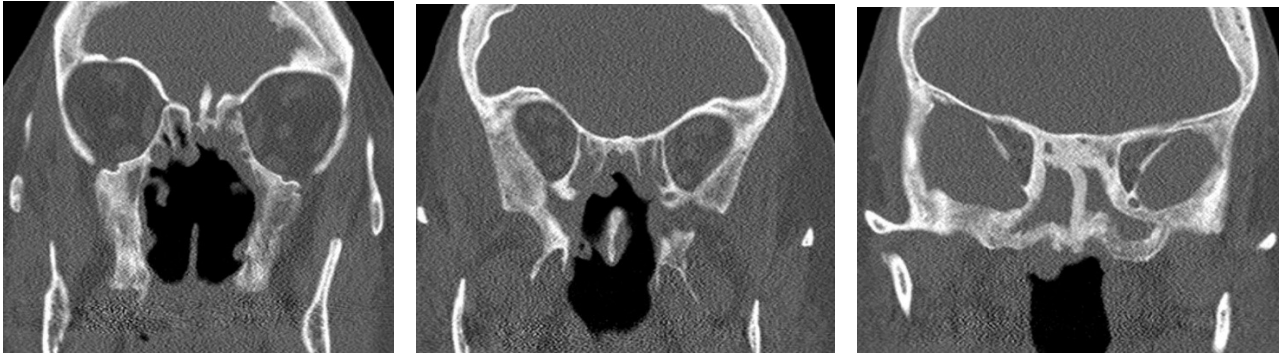
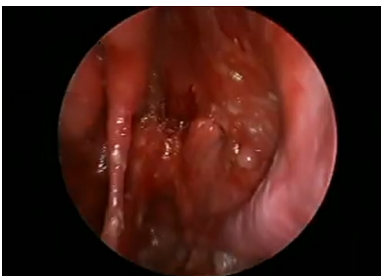
Figure 1: Coronal Sinus CT (continued)

The patient was treated with rituximab, and BID nasal irrigations using budesonide and mupirocin. One year after initiation of treatment she had dramatic improvement of her symptoms and was able to discontinue systemic steroids and methotrexate.

During her last visit, two years after initiation of treatment, the patient continues to improve and nasal endoscopy showed reduced mucosal inflammation and minimal crusting (Video).



Video: Nasal endoscopy two years after initiation of rituximab infusions.

Discussion

There is ample data in the literature indicating that sinus surgery in patients with granulomatosis with polyangiitis should be avoided unless absolutely necessary and some indicate that sinus surgery in these patients results in worsening osteitis post-operatively¹. Emergency sinus surgery for complications and pyoceles should be performed while systemic therapy is initiated toward remission of the disease. If non-emergency sinus surgery is ever needed, it should be performed after systemic remission is achieved². If scar tissue has caused nasal airway obstruction, surgical treatment will be beneficial to the patient, but only after disease quiescence is achieved. Septal perforation repair can be attempted only after the disease is systemically controlled for at least a year.

Conclusion

Routine endoscopic sinus surgery and septoplasty in patients with granulomatosis with polyangiitis should be avoided. Routine sinonasal surgical intervention in these patients should be attempted only after systemic control of the disease for at least a year.

References:

1. Holme SS, Moen JM, Kilian K, Eggesbø HB, Molberg Ø. Impact of Paranasal Sinus Surgery in Granulomatosis With Polyangiitis: A Longitudinal Computed Tomography Study. *Laryngoscope*. 2020 Aug;130(8):E460-E468.
2. Kohanski MA, Reh DD. Granulomatous diseases and chronic sinusitis. *Am J Rhinol Allergy* 2013; 27, S39 –S41.